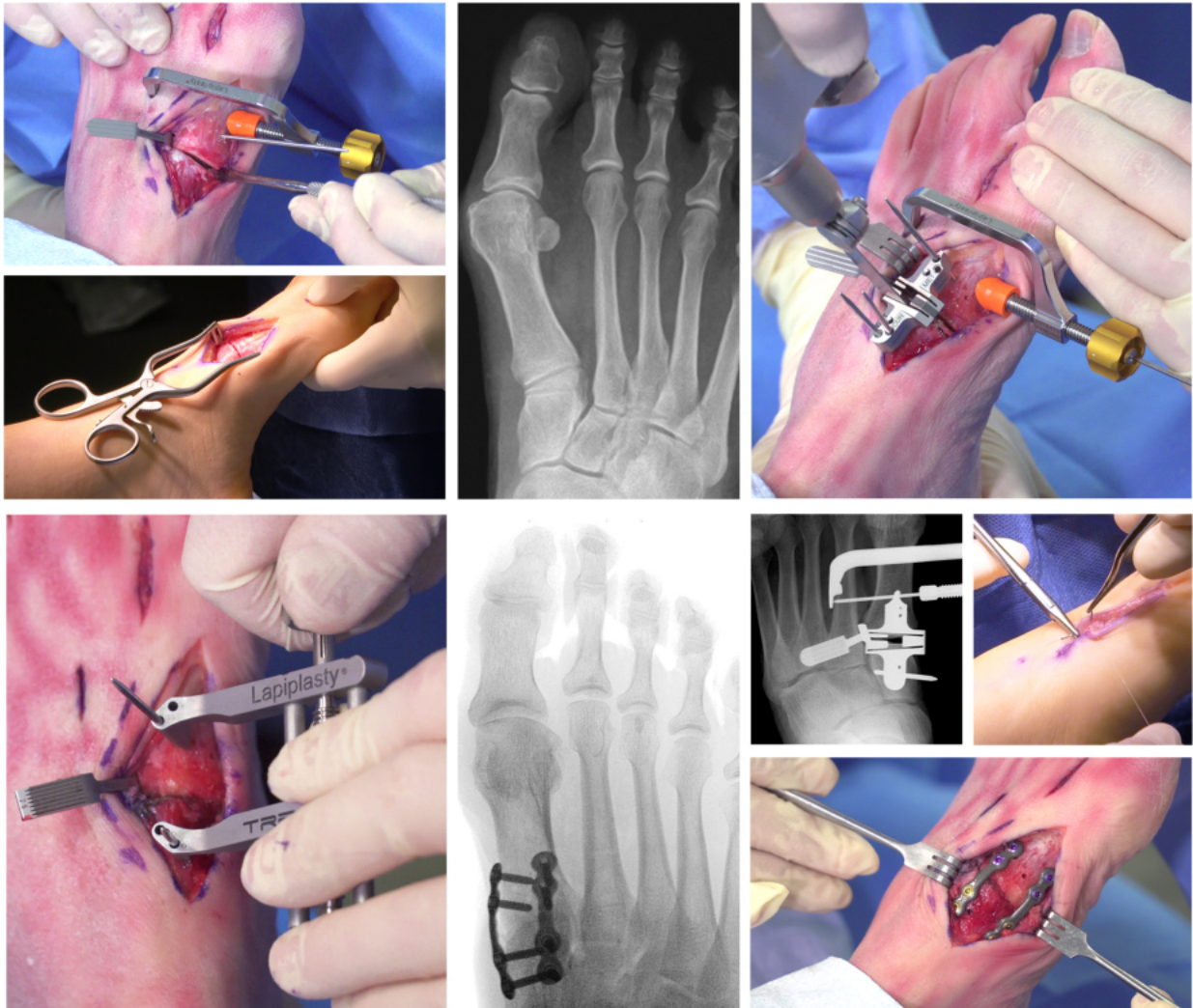


# Lapiplasty®

3-Plane Correction at the CORA

## Surgical Technique Guide



*Prior to the use of the system, the surgeon should refer to the appropriate instructions for use (TMC Plating System, LBL 1405-9005; TMC Compression Screw System, LBL 1405-9056) for complete warnings, precautions, indications, contraindications, and adverse events.*

## Table of Contents

Operating Room Set Up	1
Pre-Operative Planning	1
Metatarsal Frontal-Plane Rotation	2
Patient Set Up	3
Fluoroscopy Tip	4
Direct Dorsal Incision	5-7
1st TMT Joint Release	8
1st MTP Lateral Release	9
Trial Manual Reduction	10-11
Positioner Incision	12
Fulcrum Insertion	13
Fulcrum Selection	14
3-Plane Correction with Positioner and Fulcrum	15-17
Secure 3-Plane Correction	18
Joint Seeker Insertion	19
Cut Guide Selection	20
Cut Guide Application	21
Secure the Cut Guide	22
Confirm Cut Guide Alignment	23
Precision Cuts with Cut Guide	24
Removal of Bone Slices	25-26
Prepare the Joint Surfaces	27
Joint Apposition with the Compressor	28
Confirm Joint Apposition	29
Insert Lateral Interfrag Screw <i>[Alternative Option]</i>	30-31
Provisional Fixation with Threaded Olive Wire	32-33
Apply Medial Biplanar™ Plate First <i>[Alternative Option]</i>	34
Apply 2nd Provisional Fixation Wire	35
Confirm Provisional Fixation	36
Apply Dorsolateral Biplanar Plate	37-39
Insert Locking Screws in Dorsolateral Plate	40
Apply Medial Biplanar™ Plates	41-42
Confirm Three-Plane Correction	43
Insert Transverse Screw <i>[Alternative Option]</i>	44-47
Final Incision Closure	48

## Operating Room Set Up

---

In addition to standard small-joint instrumentation, the following items should be available in the operating room:

- Intra-operative fluoroscopy (mini c-arm recommended for maneuverability)
- Straight ¼ or ½ inch osteotomes
- Pituitary or long skinny (i.e. synovectomy) rongeur
- Small bone power: sagittal saw, 1.6mm & 2mm K-wire driver

**Note:** Treace Medical Concepts offers 40x11x0.51mm Lapiplasty® saw blades compatible with Stryker (SM-4011) and Hall-Linvatec (ZMS-4011) sagittal saw systems.

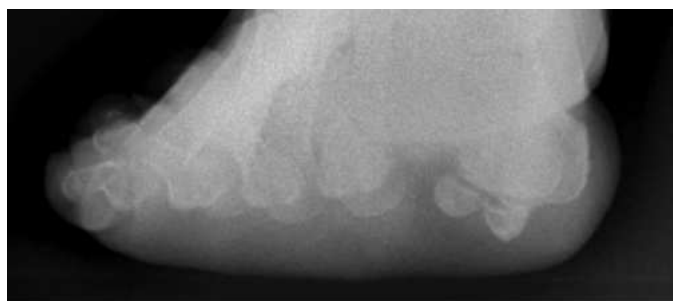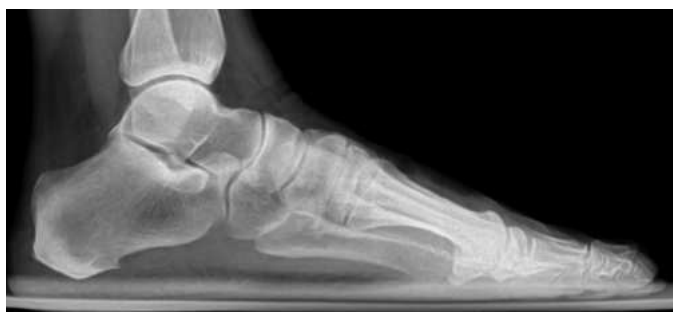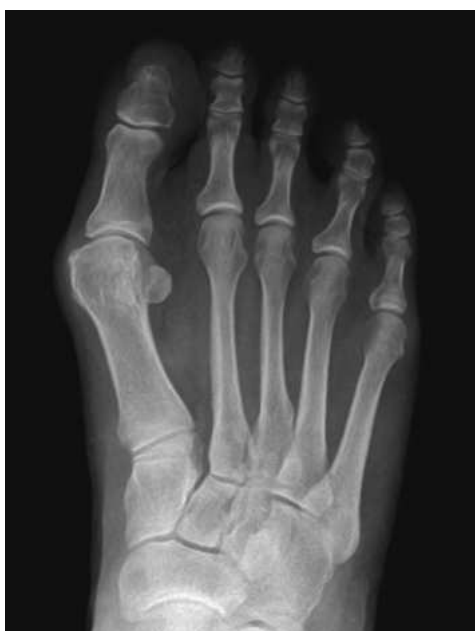The Lapiplasty® System sterile-packed plate and screw kits are composed of a variety of plate designs and screw sizes. The correct plate and screw selection for the procedure is extremely important, and pre-operative consideration of the proper fixation option will increase the potential for surgical success.

## Pre-operative Planning

---

Pre-operative assessment of all three planes of the Hallux Valgus deformity is critical for proper patient selection and pre-operative planning. A weight-bearing anterior-posterior (AP) (left), Lateral (upper right), and Axial Sesamoid (lower right) view should be assessed for all patients. The Axial Sesamoid view is critical for assessing metatarsal frontal-plane rotation (i.e. pronation), sesamoid subluxation, and erosion of the metatarsal crista.

**Note:** Though the sesamoids will commonly appear to be subluxed in the AP view, the apparent subluxation can often be due to a metatarsal that is rotated in the frontal-plane.

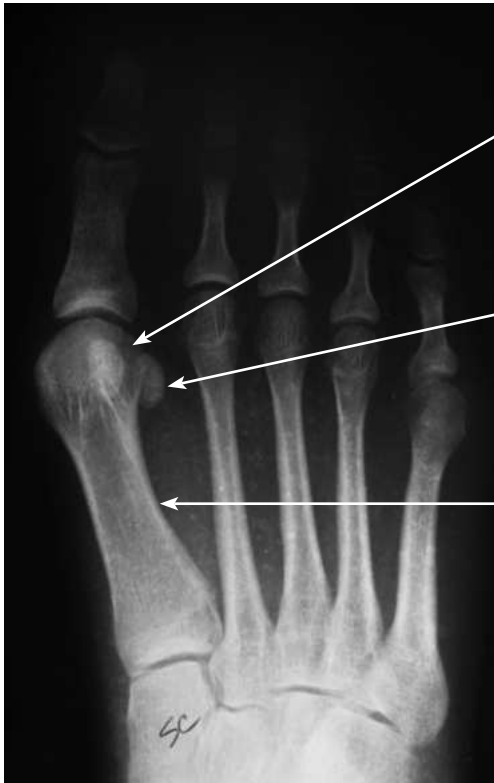

# Metatarsal Frontal-Plane Rotation

---

Recognizing radiographic indicators of metatarsal frontal-plane rotation in the AP X-ray is essential for intra-operative fluoro guidance during the procedure. The presence or absence of the metatarsal “lateral round sign” is a particularly helpful radiographic indicators of metatarsal frontal-plane rotation.

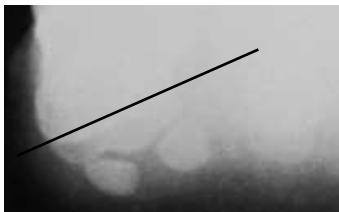
## Hallux Valgus



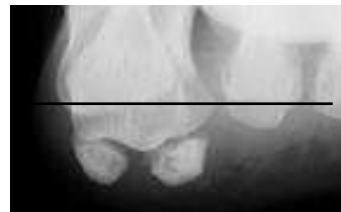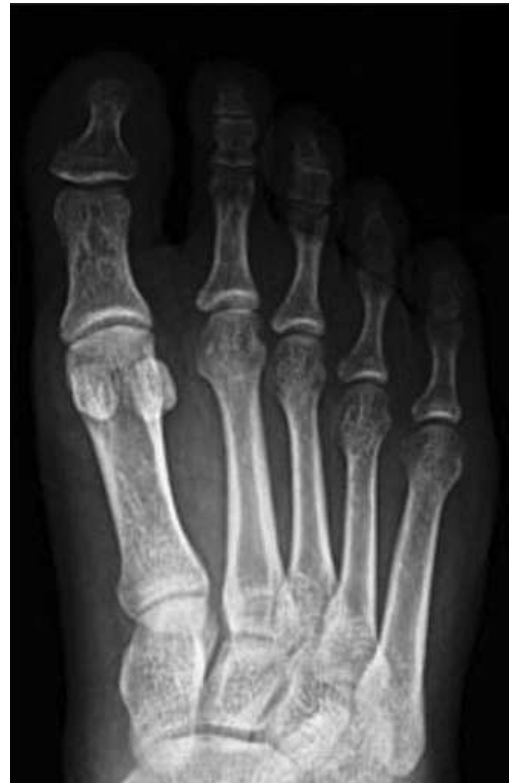Lateral rounding of metatarsal head (profile of plantar condyle)

Apparent lateral displacement of sesamoids

Lateral bowing of metatarsal shaft



## Normal

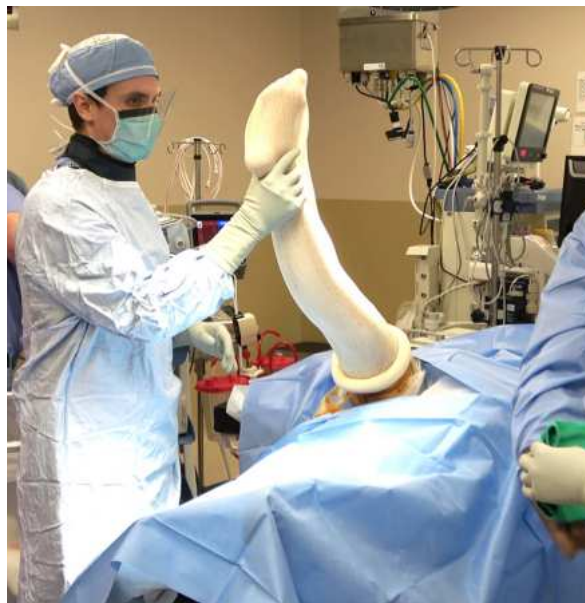

## Patient Set Up

---

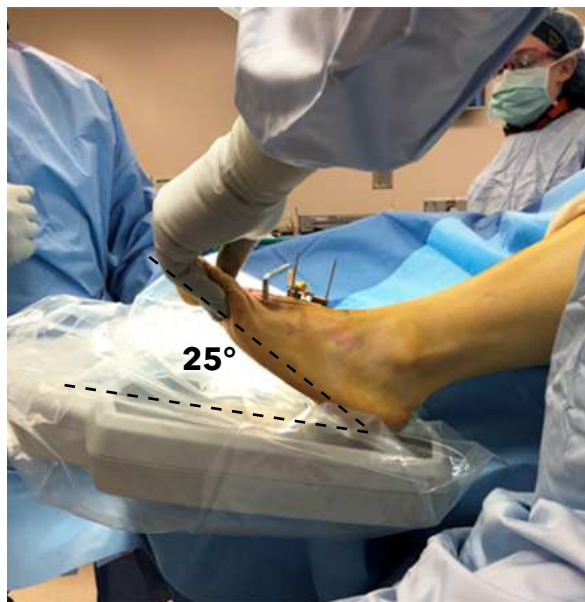Position the patient supine with the ipsilateral hip bumped to position the foot in the sagittal plane. Generally, a thigh tourniquet is recommended for hemostasis so that the leg/foot can be freely maneuvered intra-operatively for fluoro views.

**Note:** *An ankle tourniquet may restrict motion of the ankle tendons and can make it difficult to maneuver the foot for fluoro views.*



Position the operative foot at the end of the table and orient the c-arm such that fluoro views can be easily obtained. It is recommended to position the c-arm in a consistent orientation throughout the case, manipulating the orientation of the foot to obtain the desired fluoro views.

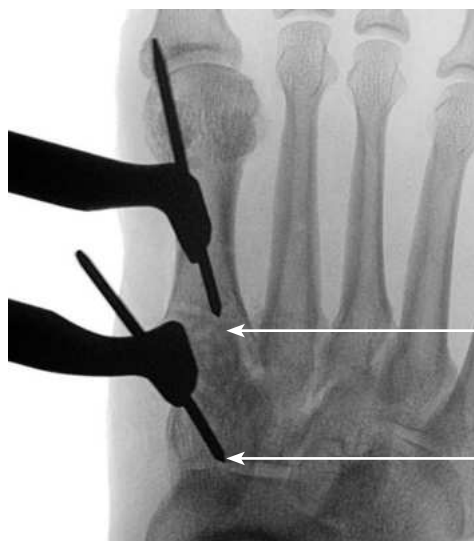
**Note:** *The foot will often be dorsiflexed 20°-25° throughout the case to obtain a “down the joint” AP view.*



## Fluoroscopy Tip

---

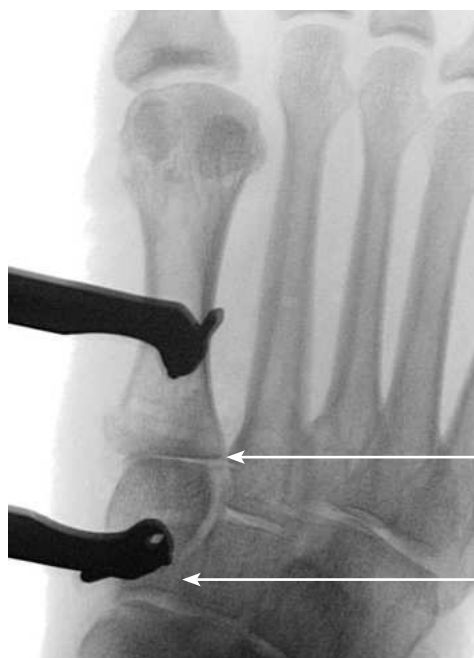Example fluoro view that is not parallel with the TMT joint line. Note, if the X-ray angle is not oriented “down the joint”, then the TMT joint surfaces cannot be assessed.



1st TMT joint  
is not  
visualized

Fluoro not  
directed  
directly down  
pins

When the foot is dorsiflexed 20°-25° (going “live” when necessary), the c-arm beam is oriented parallel with the joint surfaces to obtain the “down the joint” fluoro view.



1st TMT  
joint is  
visualized

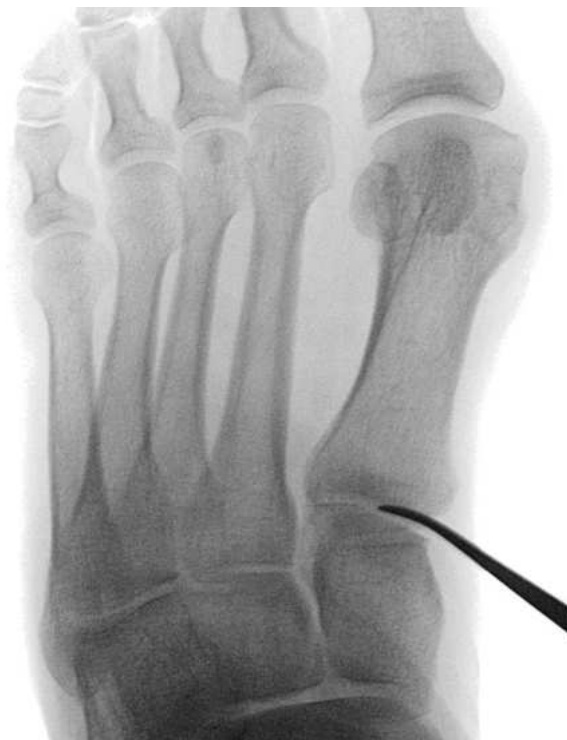Fluoro  
directed  
directly  
down pin  
(pin “disap-  
pears”)



## Direct Dorsal Incision

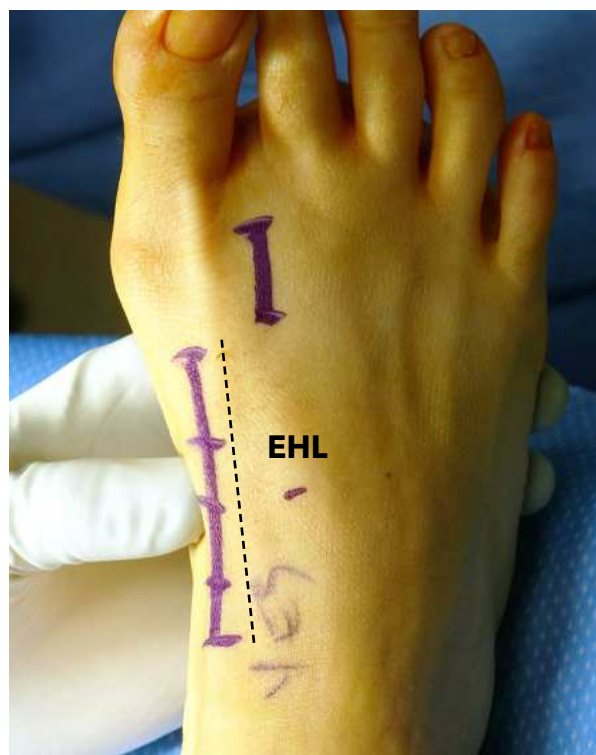---

Utilize fluoro to locate and mark the location of the 1st TMT joint line with a freer prior to making an incision.



The incision should be direct dorsal, along the medial margin of the extensor hallucis longus (EHL) tendon. Extend the incision from the proximal pole of the cuneiform to the midshaft of the metatarsal for sufficient access to the pertinent landmarks without the need for excessive tissue retraction.

**Note:** *It is critical that the incision is made direct dorsal, as a medially-biased incision may not allow for proper positioning of the Fulcrum and Cut Guide.*

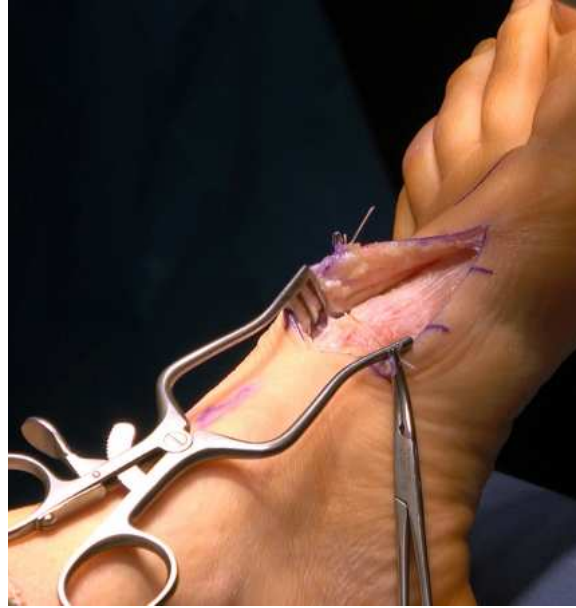

## Direct Dorsal Incision (cont'd)

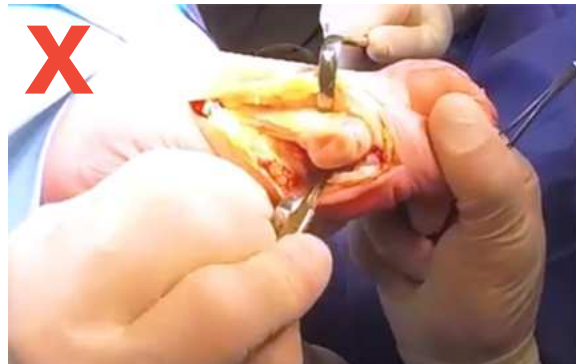---

Deepen the incision through the fascial layers to the capsule of the 1st TMT joint. Dissection is carried deep to the capsule and periosteum using sharp sub-periosteal dissection.

**Note:** Take care to identify and protect the superficial branch of the cutaneous nerve that can often pass through the surgical site.



**Note:** Do not perform a medial MTP release and/or metatarsal eminence resection at this time. Release of the medial capsular tissue can destabilize the sesamoid "sling" and prevent the sesamoids from rotating with the metatarsal.

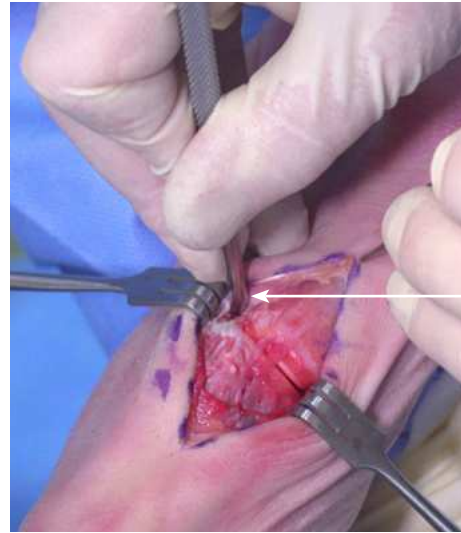



## Direct Dorsal Incision (cont'd)

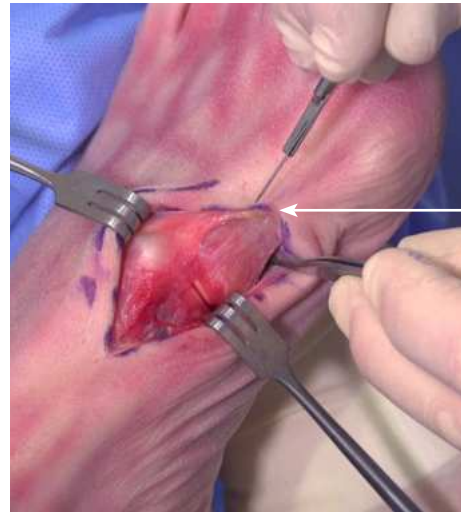---

Utilize a freer to create a pocket for the **Fulcrum** as far proximal as possible (with the proximal edge touching the cuneiform) between the base of the 1st and 2nd metatarsals. Perform minimal dissection in the interspace area to prevent migration of the Fulcrum.



Create pocket for **Fulcrum** as far proximal as possible

Extend the subperiosteal dissection distally and plantarly to expose the medial ridge of the 1st metatarsal. The cup of the **Positioner** will directly engage this ridge at a later step.



Expose the Metatarsal medial ridge for **Positioner**

# 1st TMT Joint Release

---

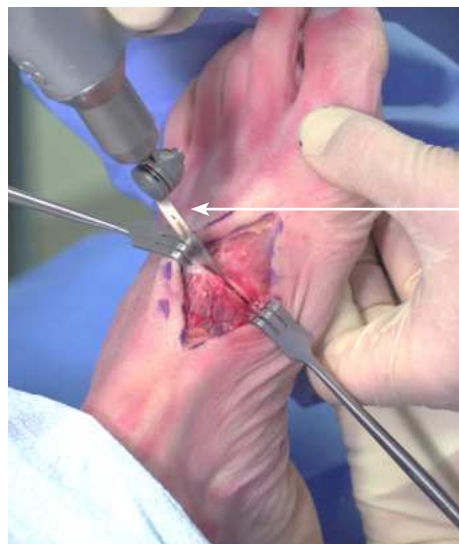
While retracting the EHL laterally and temporarily distracting the metatarsal to gap the 1st TMT joint, insert the unpowered sagittal saw blade approximately half-way down the 1st TMT joint. Then power it on, running the blade up and down the joint to flatten the surfaces for congruent frontal-plane rotation.

**Note:** The hole in the 40mm saw blade represents a 30mm depth, providing a reference for the approximate depth of the average 1st TMT joint.

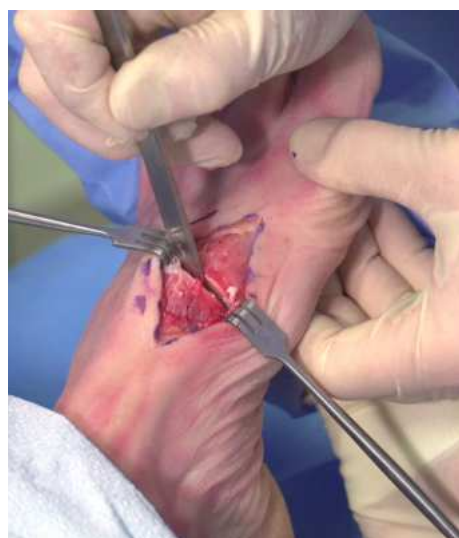**Note:** Avoid application of excessive downward pressure when planing the joint as this can cause the saw blade to deviate from following the joint line.

A straight osteotome is then employed in the 1st TMT joint to release any remaining capsular or plantar ligament attachments for full mobilization of the metatarsal. Special attention is paid to ensure release of the plantar-lateral ligamentous attachments.

**Note:** A complete release of the plantar tissue allows for easier removal of the bone slices later in the procedure.



Reference  
hole in  
blade at  
30mm

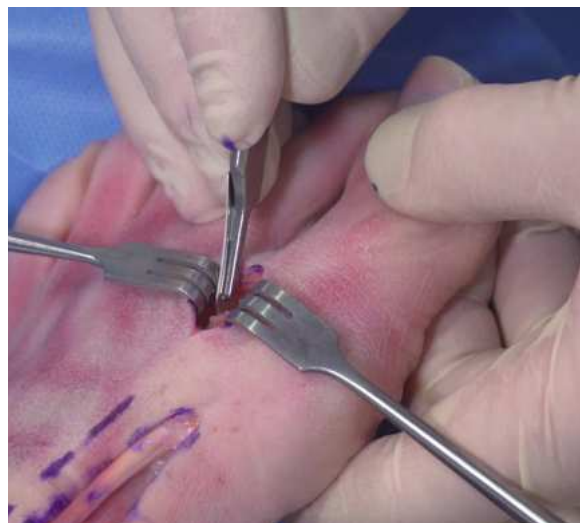

# 1st MTP Lateral Release

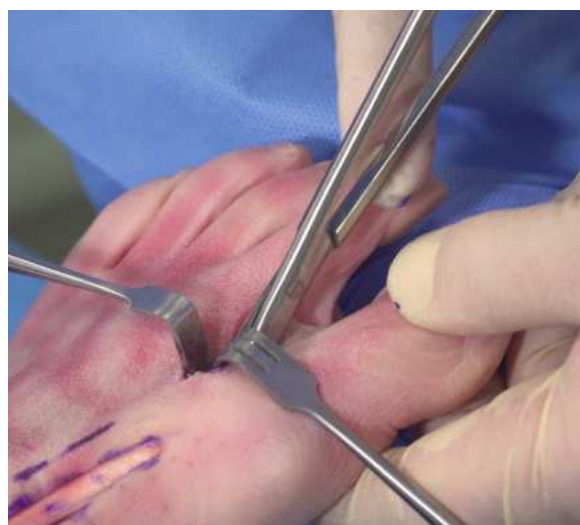---

Create a small interspace incision at the lateral aspect of the 1st MTP joint in order to perform a minimal lateral release of the contracted tissue. Under direct visualization, perform a lateral capsulotomy and a release of the sesamoidal accessory ligament.

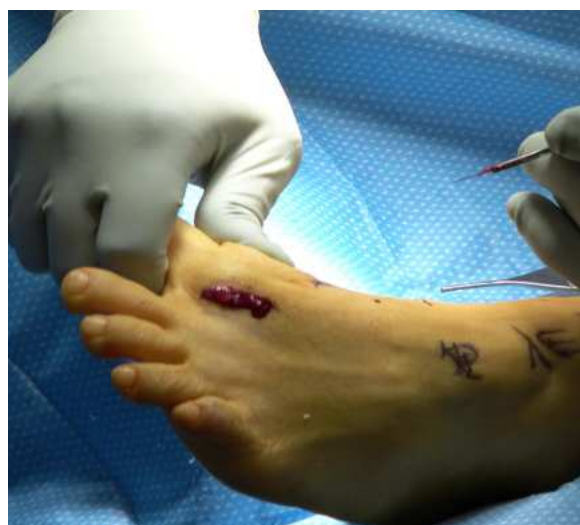**Note:** *It is not required to release the adductor tendon.*



Scissors can be used for additional release of the proximal attachment of the sesamoids, particularly in the case of significant ankylosis and/or sesamoid subluxation.



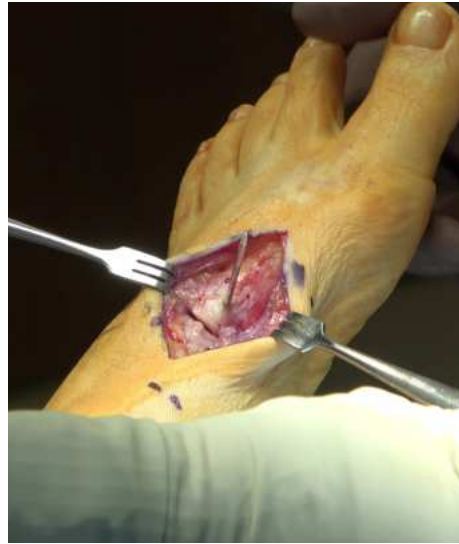Firm manual manipulation of the great toe into plantarflexion and varus is performed to ensure a complete release of the lateral capsular tissues.



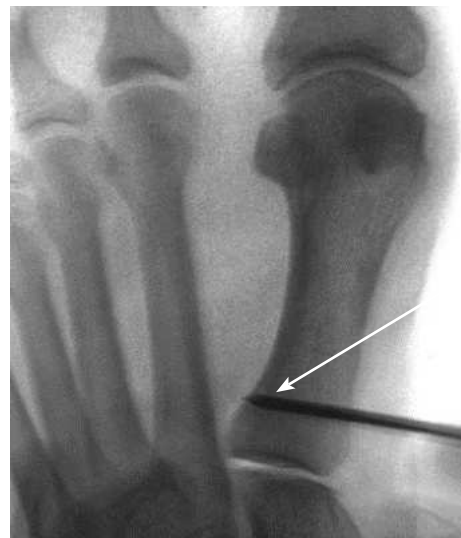## Trial Manual Reduction

---

Insert a short 2mm “joystick” half-pin into the metatarsal approximately 1cm distal to the 1st TMT joint from a dorsomedial (2:00 or 10:00) orientation.



Orient the pin parallel with the 1st TMT joint (approximately aimed at the head of the 5th metatarsal) such that the proximal end will not interfere with the **Positioner**. Check that the tip of the pin does not extend into the 2nd metatarsal.

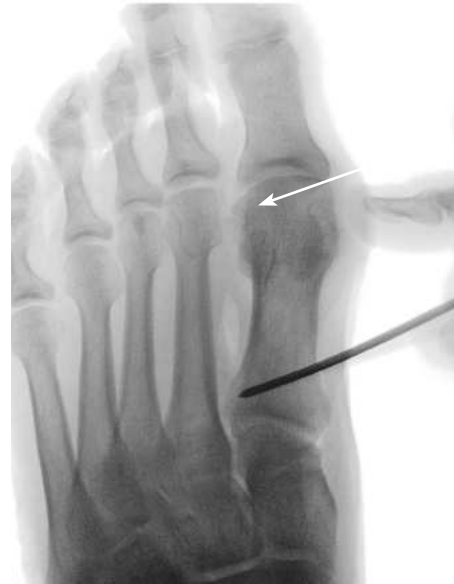

Joystick  
pin  
oriented  
parallel  
with 1st  
TMT joint

## Trial Manual Reduction (cont'd)

While holding the foot stable, perform a “trial manual reduction” under live fluoro by rotating the joystick pin laterally and manually applying pressure to the metatarsal head. Confirm elimination of the “lateral round sign” and centering of the sesamoids with minimal manual pressure.

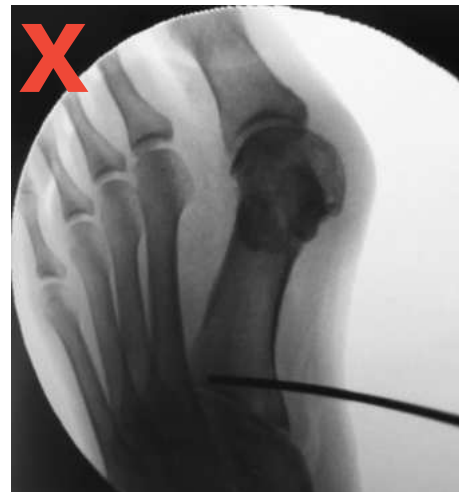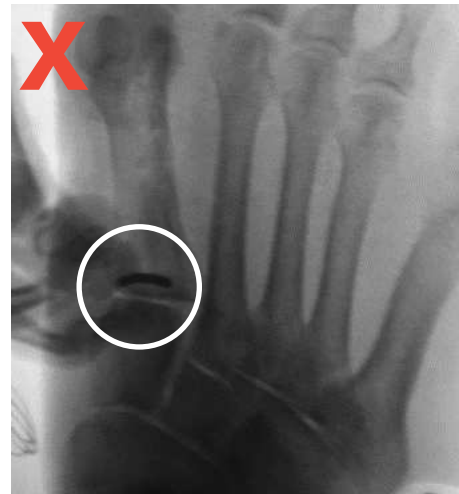**Note:** *When properly released, the 1st metatarsal should freely rotate approximately 20-30°.*



Elimination of “lateral round sign”

If the entire foot is rotating and/or significant bending of the joystick pin is necessary for complete trial reduction, then the 1st TMT joint and/or distal lateral release has not been adequately performed.

**Note:** *If complete manual reduction is not easily achieved, reassess the 1st TMT/MTP releases and repeat the above assessment until manual reduction can be demonstrated.*

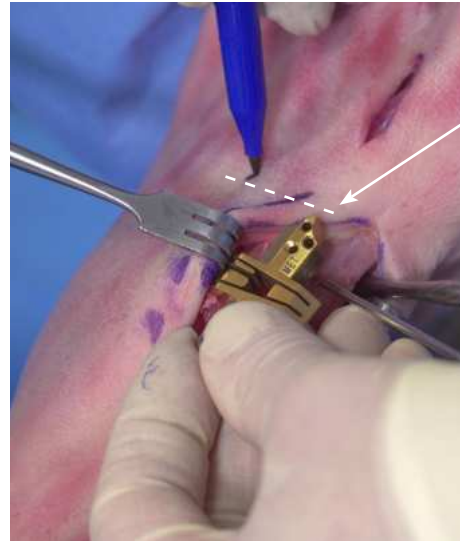




## Positioner Incision

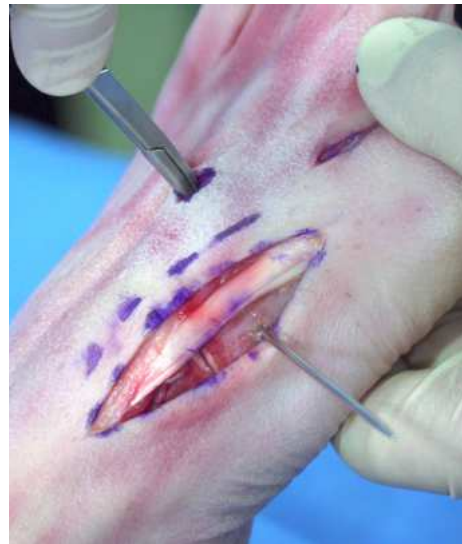---

The **Cut Guide** is utilized as a reference for the incision over the 2nd metatarsal for the **Positioner**. With the **Cut Guide** centered over the 1st TMT joint, make a mark over the 2nd metatarsal that is 2-3mm distal to the tip of the **Cut Guide**.



Mark incision for **Positioner** 2-3mm distal to **Cut Guide**

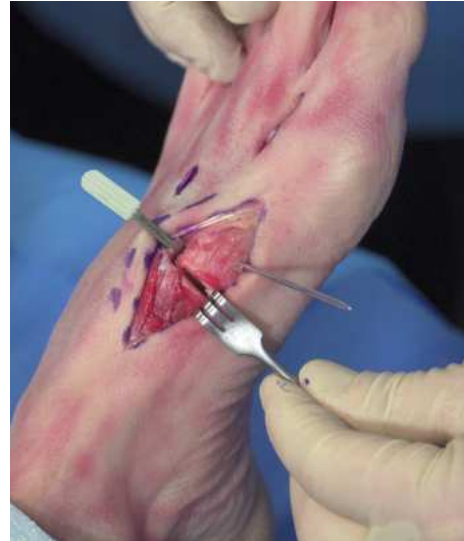Create a percutaneous incision over the 2nd metatarsal and bluntly dissect the soft tissue away from the lateral aspect of the 2nd metatarsal. The depth stop of the **Positioner** tip will be inserted into the incision and will sit directly on the dorsolateral cortex of the 2nd metatarsal.



## Fulcrum Insertion

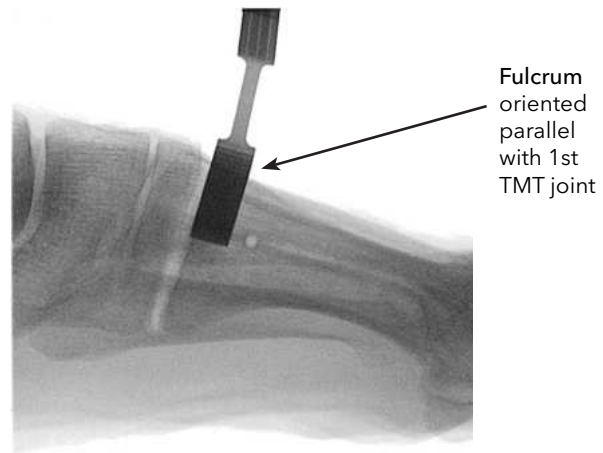
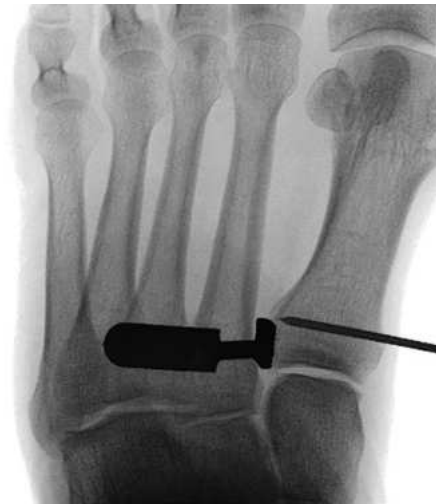---

Punch the **Fulcrum** into the pocket created between the base of the 1st and 2nd metatarsals, as far proximal as possible (its proximal edge should touch the cuneiform) and parallel with the 1st TMT joint in the sagittal plane, to ensure the **Fulcrum** is optimally positioned as a pivot point.



Fluoro can be used to confirm proximal placement of the **Fulcrum**, with its proximal edge approximately at the level of the 1st TMT joint, and orientation parallel with the declination of the 1st TMT joint in the sagittal plane.

**Note:** Check the **Fulcrum** throughout the procedure to ensure that it does not shift out of the correct position. If it does, completely remove the **Fulcrum** and reinsert it in the proper position.

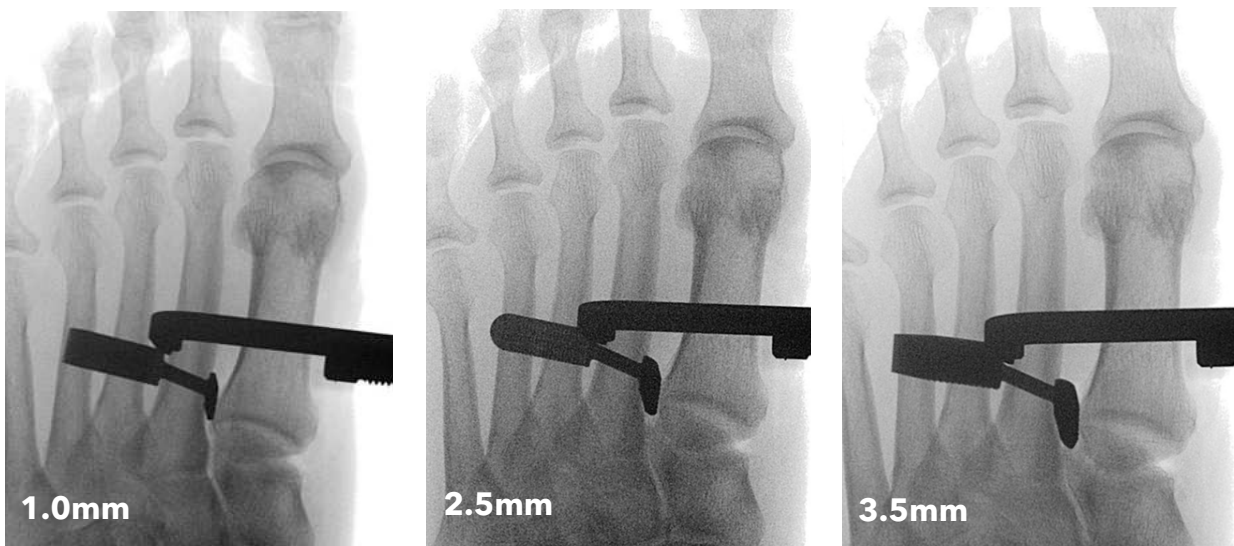


## Fulcrum Selection

---

Selection of the proper Fulcrum thickness is critical for achieving a complete correction, i.e. true intermetatarsal angle (IMA) of zero degree. Images demonstrate the effect of the 1mm (left), 2.5mm (center), and 3.5mm (right) Fulcrum.

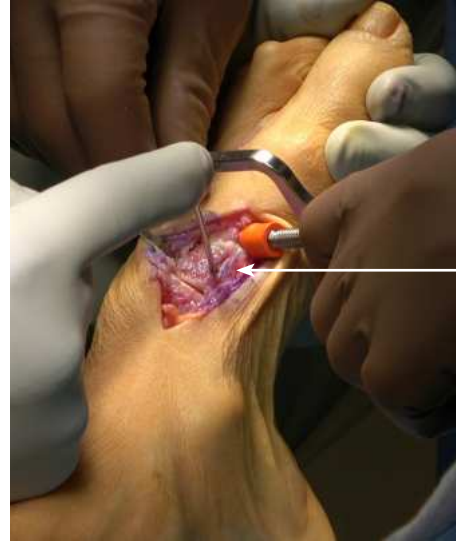**Note:** A larger size **Fulcrum** may be considered for a large 1st – 2nd metatarsal diastasis and/or if the IMA cannot be fully reduced with the **Positioner**.



## 3-Plane Correction with Positioner and Fulcrum

Insert the tip of the **Positioner** over the 2nd metatarsal (with the “depth stop” on the dorsolateral aspect of the 2nd metatarsal) and position the orange cup to engage the medial ridge of the 1st metatarsal. To correct all 3 planes of the deformity, utilize the joystick pin to rotate the metatarsal while the Positioner is tightened to “two finger tightness”.

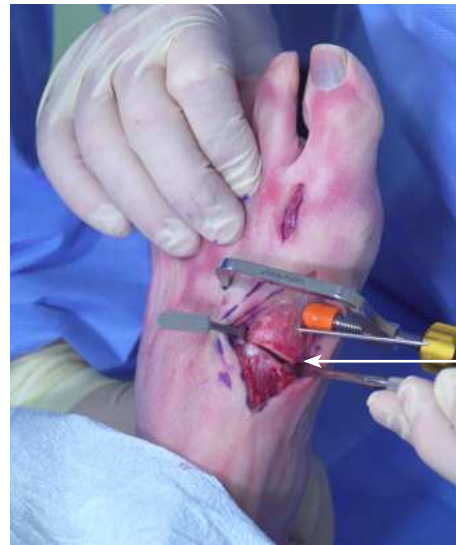**Note:** Take care to not overtighten the **Positioner**, as overtightening can pull the 2nd metatarsal medially and/or cause the 1st metatarsal to dorsi-flex/gap plantarly.



Assist correction by rotating joystick pin

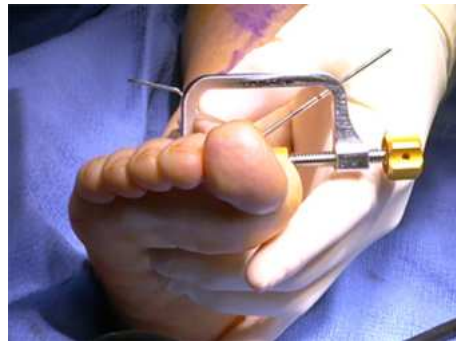Clinically, confirm that application of the **Positioner** completely reduced the deformity, pivoting the 1st metatarsal about the **Fulcrum** resulting in medial gapping at the 1st TMT joint. Check that the dorsal cortex of the 1st metatarsal and cuneiform are aligned (i.e. 1st metatarsal base did not translate plantarly or dorsally).

**Note:** After applying the **Positioner**, check that the **Fulcrum** remains in its proper position and did not shift, rotate, or squeeze out dorsally.



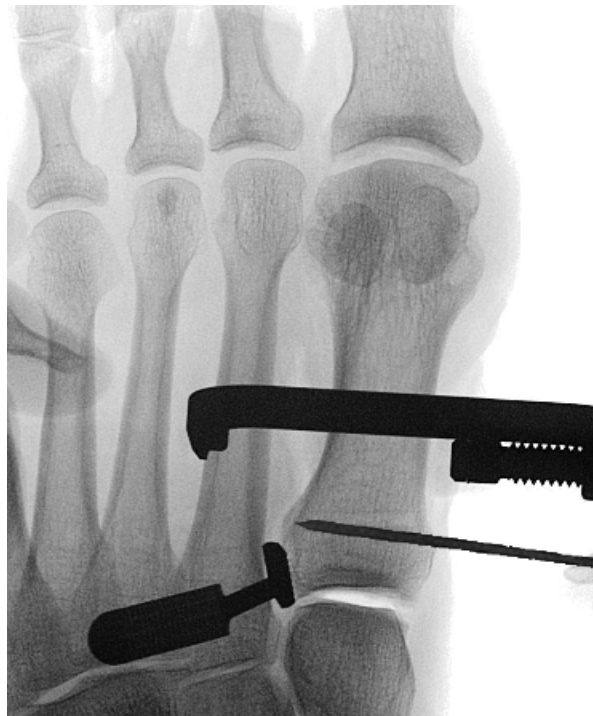Medial gapping of 1st TMT joint is expected with correction

Check that the arm of the **Positioner** is level in the frontal plane. If the tip or knob of the **Positioner** is tilted up or down in the frontal plane, remove the **Positioner** and reapply it.



### 3-Plane Correction with Positioner and Fulcrum (cont'd) \_\_\_\_\_

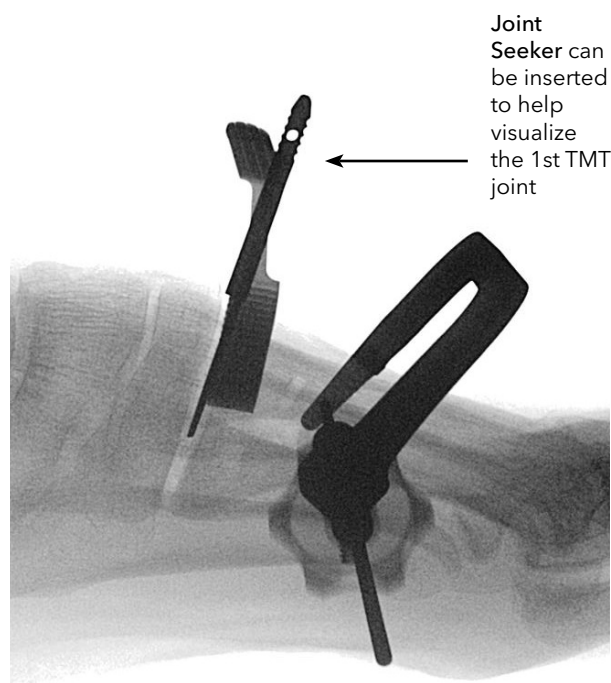
Fluoro is used to confirm complete 3-plane correction, checking for medial gapping of the 1st TMT joint (in the “down the joint” view) in addition to full reduction of the IMA, HVA, lateral round sign, and sesamoid position.



A lateral fluoro is utilized to confirm that the TMT joint is not plantar-gapped, the metatarsal is not dorsiflexed and/or translated dorsally or plantarly. The **Joint Seeker** can be inserted to help identify and visualize the 1st TMT joint.

**Note:** A rigid, flat surface can be used to apply plantar pressure to the foot when obtaining lateral views.

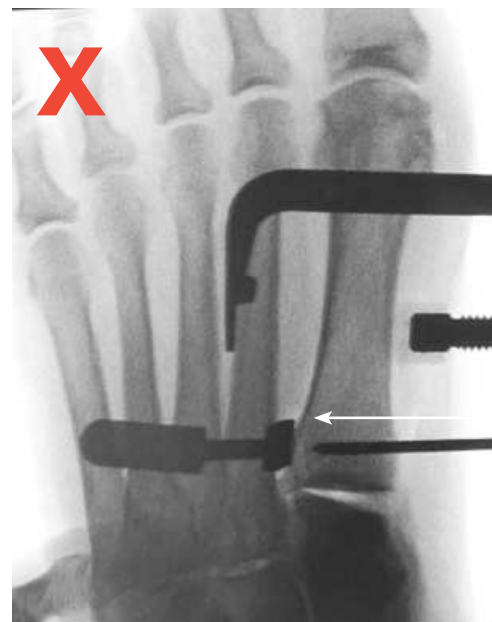
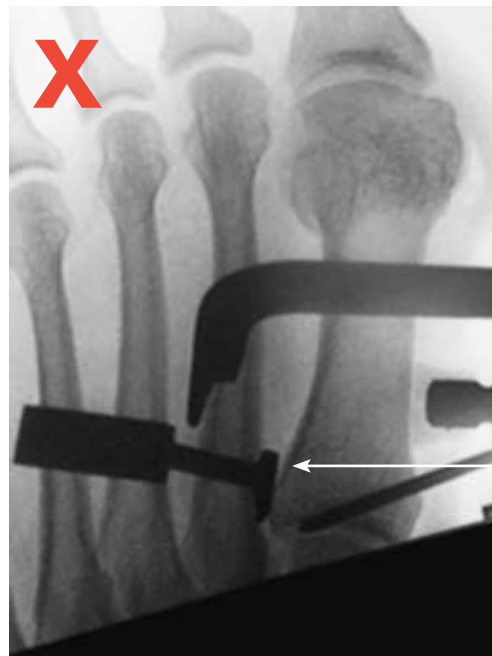
**Note:** The metatarsal alignment at this step will dictate the final alignment, so do not proceed if the alignment is not correct in all three planes.





### 3-Plane Correction with Positioner and Fulcrum (cont'd) \_\_\_\_\_

Confirmation of proper Fulcrum size and position is critical for a complete correction. After application of the Positioner, critically evaluate the fluoro views to confirm that the proper **Fulcrum** size and position. Specifically, assess whether the **Fulcrum** is too thin to achieve complete IMA reduction and that it didn't slide distally.

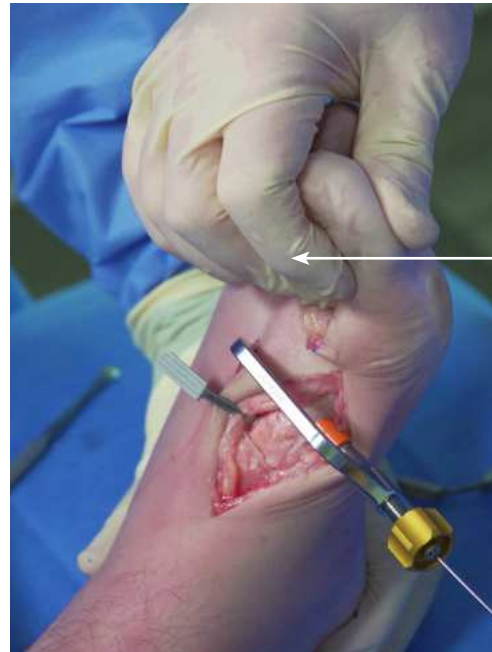

## Secure 3-Plane Correction

---

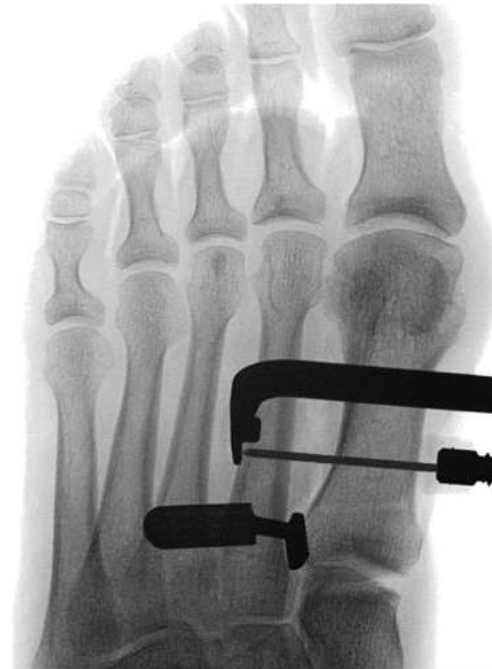To secure the correction in place, drive a 1.6mm K-wire through the cannulation in the **Positioner**, feeling it go through three cortices until reaching a “hard stop” when it contacts the **Positioner** tip.

**Note:** For additional plantarflexion of the 1st metatarsal, manually force the hallux into dorsiflexion to engage the windlass mechanism and plantarflex the metatarsal while driving the K-wire through the **Positioner**.



Manually dorsiflex the hallux to plantarflex the Metatarsal (windlass mechanism)

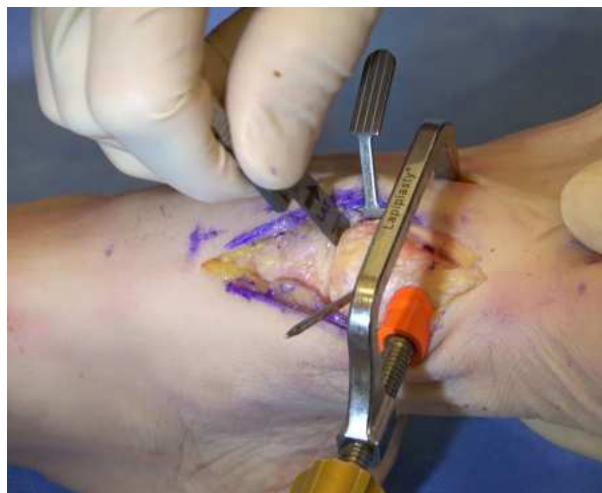Use fluoro to confirm position of the K-wire fully into the 2nd metatarsal and maintenance of the correction.



## Joint Seeker Insertion

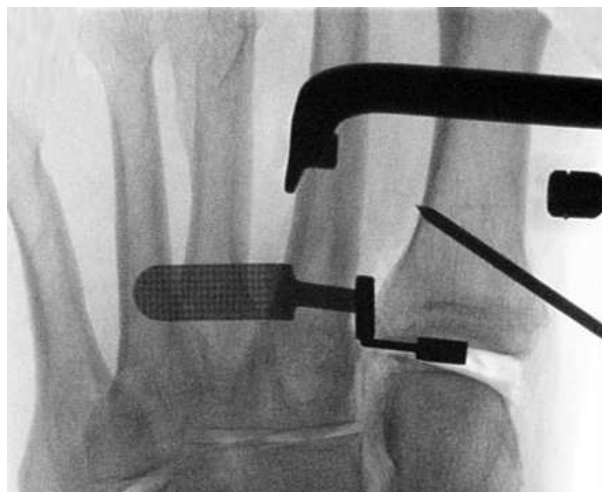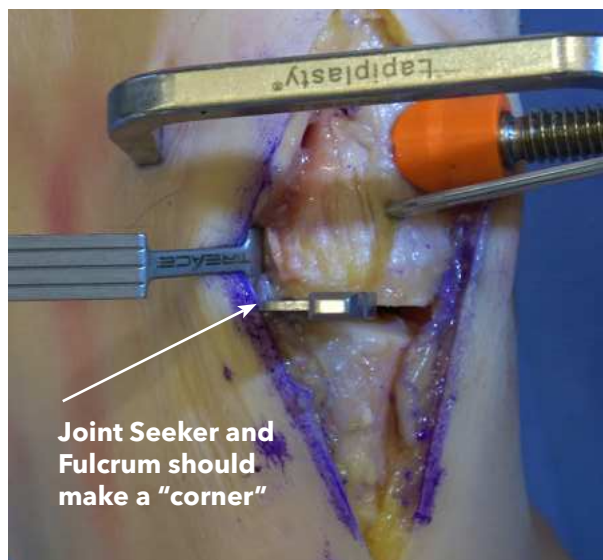
---

To set the sagittal-plane alignment of the **Cut Guide**, place the **Joint Seeker** with the arrow pointing laterally into the far lateral aspect of the 1st TMT joint (which will often be tight due to reduction of the IMA). Ensure the **Joint Seeker** is oriented straight dorsal such that the **Cut Guide** will sit directly on the dorsal cortex.



When positioned properly, the **Joint Seeker** and the **Fulcrum** should make a "corner" in the lateral aspect of the 1st TMT joint.

**Note:** If the **Joint Seeker** is difficult to insert into a tight 1st TMT joint, you can insert the **Joint Seeker** before inserting the K-wire through the Positioner and/or use a mallet to gently tap the **Joint Seeker** in place (checking to ensure the metatarsal was not translated plantarly in the process).



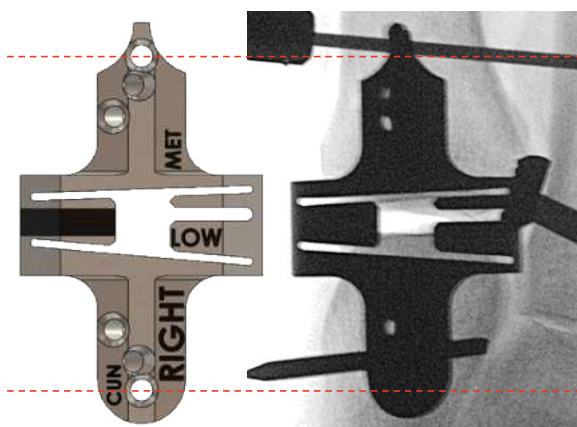
## Cut Guide Selection

---


Select the appropriate **Cut Guide** option. Consider that the Low Angle Silver (1405-2261) and Low Angle Gold (1405-2333) **Cut Guides** have the same angle cut slots, but the Low Angle Gold removes 0.75mm less overall bone (0.25mm less on metatarsal; 0.5mm less on cuneiform), thus should be reserved for cases with a short 1st Metatarsal or if it appears the Low Angle Silver **Cut Guide** is going to remove too much bone on intra-operative assessment.

**Note:** The pin holes are aligned on the Low Angle Silver and Low Angle Gold **Cut Guides** such that they can be interchanged over the same parallel pins intra-operatively when selecting the appropriate **Cut Guide** to use.

**Low Angle**



**Low Angle Gold**

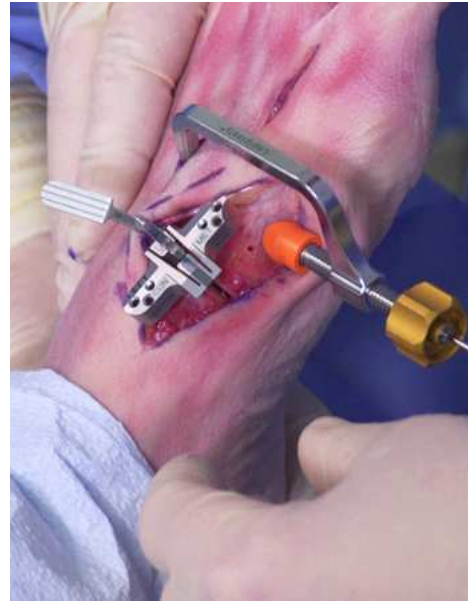

# Cut Guide Application

---

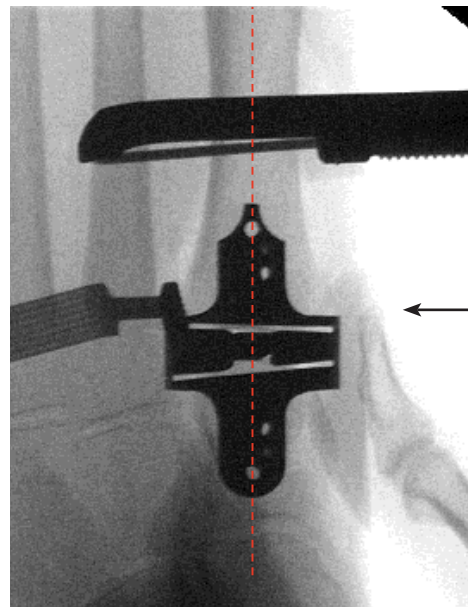
Slide the **Cut Guide** over the **Joint Seeker**, checking that the EHL tendon and skin are safely retracted out from under it. Ensure that the center of the **Cut Guide** is touching bone (though the ends will often be raised off the bone) and not tilted medially in the frontal plane on the dorsal lateral cortex of the 1st TMT joint (i.e. not tilted medially).

**Note:** Confirm that the appropriate Left/Right side of the Cut Guide is facing up and that the pointed end of the Cut Guide is directed distally.



Obtain a “down the joint” AP fluoro to confirm the **Cut Guide** is pointing down the midshaft of the 1st metatarsal. If necessary, manually adjust the tip of the **Cut Guide** under fluoro (with the **Joint Seeker** in place) to align it down the midshaft of the 1st metatarsal.

**Note:** Clinically assess the **Cut Guide** and **Joint Seeker** in the sagittal plane to confirm that the **Cut Guide** is oriented perpendicular to the 1st TMT joint line.



← If necessary, manually adjust the **Cut Guide** to point down the Metatarsal shaft



## Secure the Cut Guide

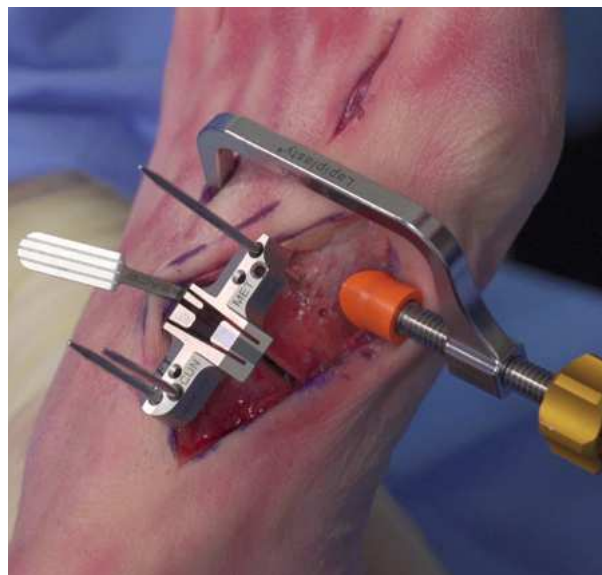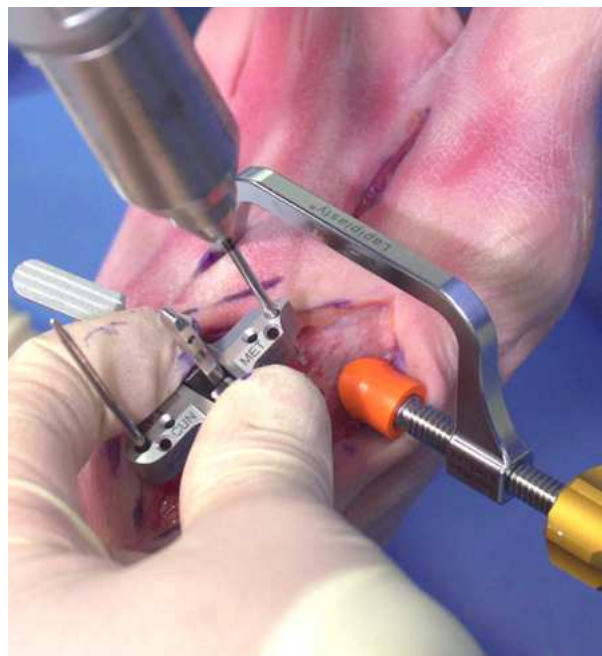---

Always hold the center of the **Cut Guide** to prevent pushing down on one end and changing the sagittal-plane orientation. Insert 2mm half-pins by hand into the most proximal and distal vertical holes until they contact bone, and then engage them with the k-wire driver to drive them bi-cortical into the respective bone.

**Note:** Confirm that the distal half-pin can be inserted without hitting the cup of the **Positioner** or the 1.6mm K-wire running through the **Positioner** cannulation.

**Note:** To reduce the chance of a pin binding in the **Cut Guide**, consider also applying saline to the **Cut Guide** holes (or soaking the **Cut Guide** in saline) and/or ensuring that the pins are oriented parallel with the holes when inserting them.

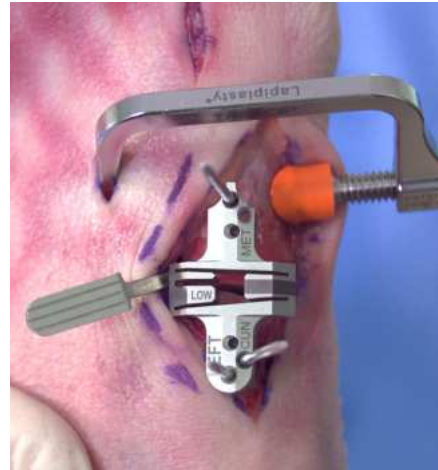
Insert a third, converging 2mm half-pin into the medial hole on the cuneiform side of the **Cut Guide**. This pin is angled 15° to prevent the **Cut Guide** from sliding up the pins while cutting. Once secured, remove the **Joint Seeker** from the center of the **Cut Guide**.



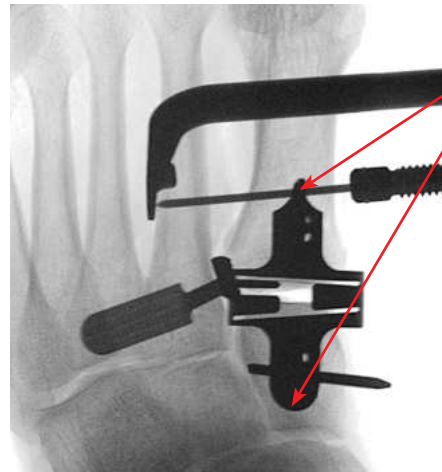
# Confirm Cut Guide Alignment

---

Assess the joint cuts clinically and with a “down the joint” AP fluoro. Confirm flat and even cut (and/or slight lateral wedge) off the metatarsal base and a laterally-wedged cuneiform cut removing the entire articular surface. If adjustment is needed, remove the pins, re-insert the **Joint Seeker**, and adjust the **Cut Guide**.

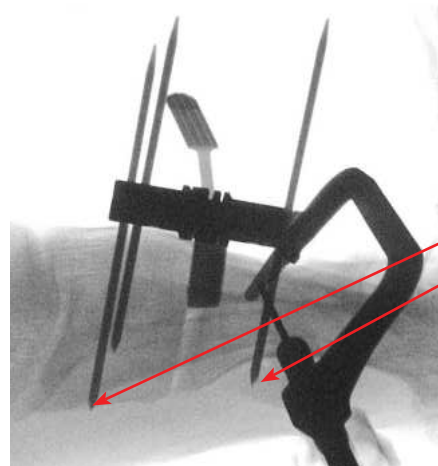


**Note:** When obtaining the proper “down the joint” AP “gunsight” fluoro view, the two vertical **Cut Guide** pins will turn to dots when the X-ray is oriented directly normal to the surface of the **Cut Guide**.



Vertical Cut Guide pins appear as “dots” in proper “gun-sight” view

Check a Lateral fluoro to confirm that the **Cut Guide** is aligned perpendicular to the 1st TMT joint and the distal/proximal pins are bi-cortical (for uniform dorsal-plantar compression in later steps with the Compressor) and parallel with the 1st TMT joint line.



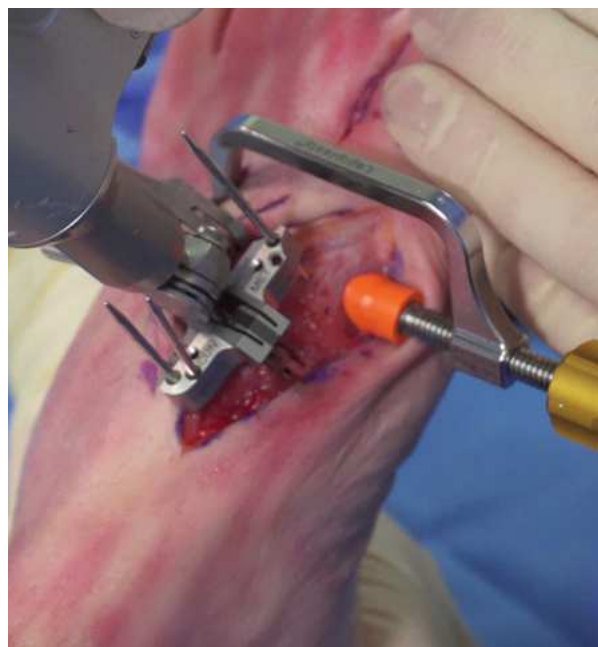
Pins are bi-cortical and parallel with 1st TMT joint

## Precision Cuts with Cut Guide

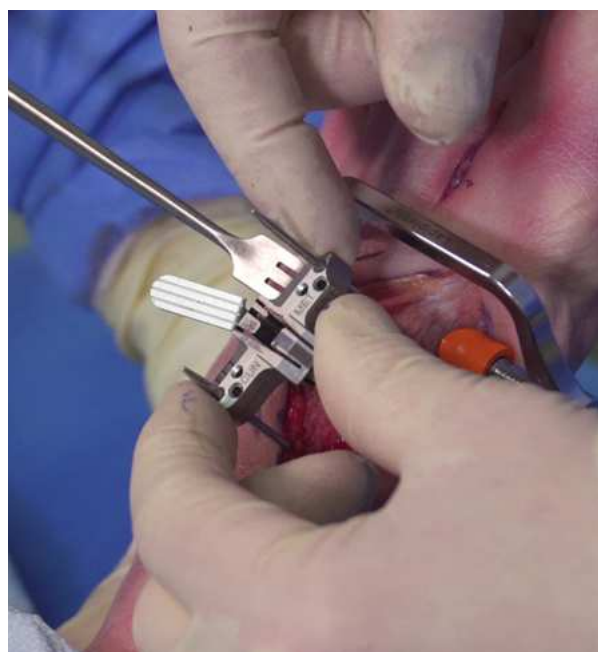
---

With the sagittal saw powered off, insert the saw blade into the lateral aspect of the metatarsal or cuneiform cut slot. While maintaining a vertical orientation of the saw, start with a up and down “pecking” motion to initiate the cut and slowly advance the full depth of the blade to extend the cuts through the plantar cortex.

**Note:** *When making saw cuts, do not drop your hand medially as this may unintentionally cut into the 2nd metatarsal.*



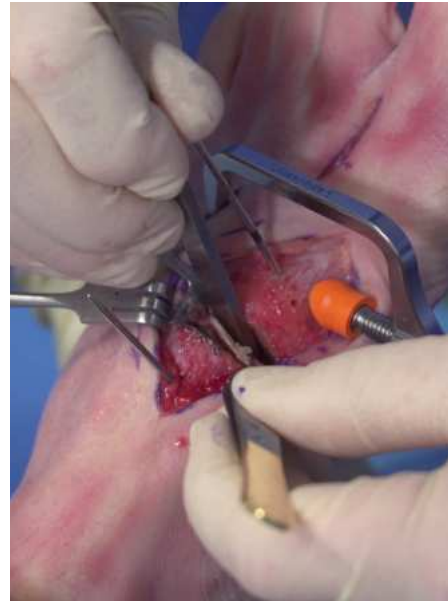After confirming complete cuts have been made on both the metatarsal and cuneiform sides, remove the converging 15° pin from the **Cut Guide** (leave the two parallel pins in for the Compressor) and slide off the **Cut Guide**. The **Positioner** and 1.6mm 1st to 2nd metatarsal pin can be removed to help access the 1st TMT joint.



## Removal of Bone Slices

---

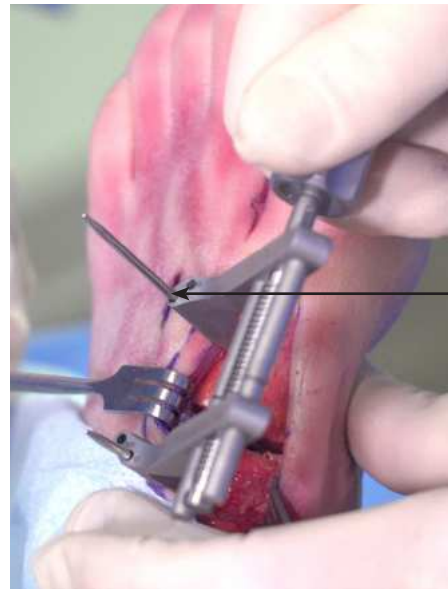A straight osteotome should be used to free up the metatarsal and cuneiform bone slices from the 1st TMT joint, making sure the cuts are fully completed through the plantar and lateral cortices.



Adjust the **Compressor** arm to center it with the two laser-marked lines on its rails and place the **Compressor** over the two parallel pins to distract open and access the 1st TMT joint. Select the appropriate holes in the **Compressor** (0° and 10° options) and slide the **Compressor** over the 2mm half-pins until it contacts the respective dorsal cortices.

**Note:** *If additional metatarsal frontal-plane rotation is desired, place the pins in the 10° metatarsal/0° cuneiform holes for a medially positioned **Compressor** or use the 0° metatarsal / 10° cuneiform holes for a laterally positioned **Compressor**.*

**Note:** *A small hemostat can be placed on one of the pins to prevent the **Compressor** from “riding up” during use.*

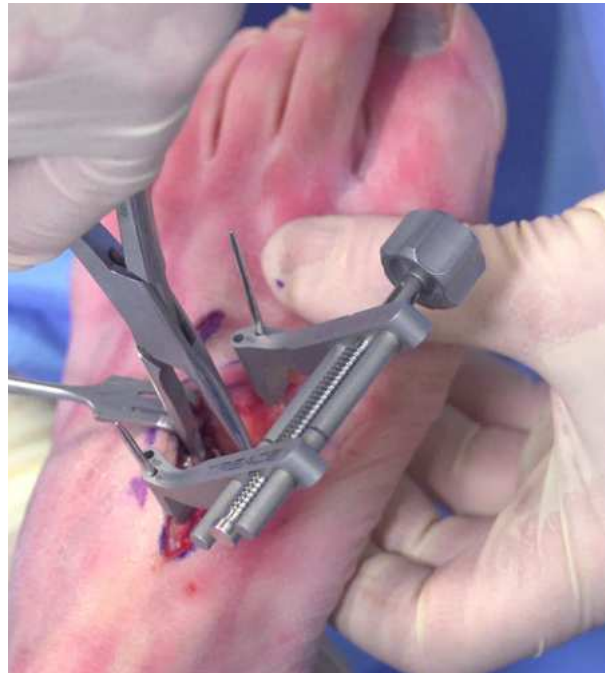

Place **Compressor** on 10° metatarsal hole for extra frontal-plane rotation

## Removal of Bone Slices (cont'd)

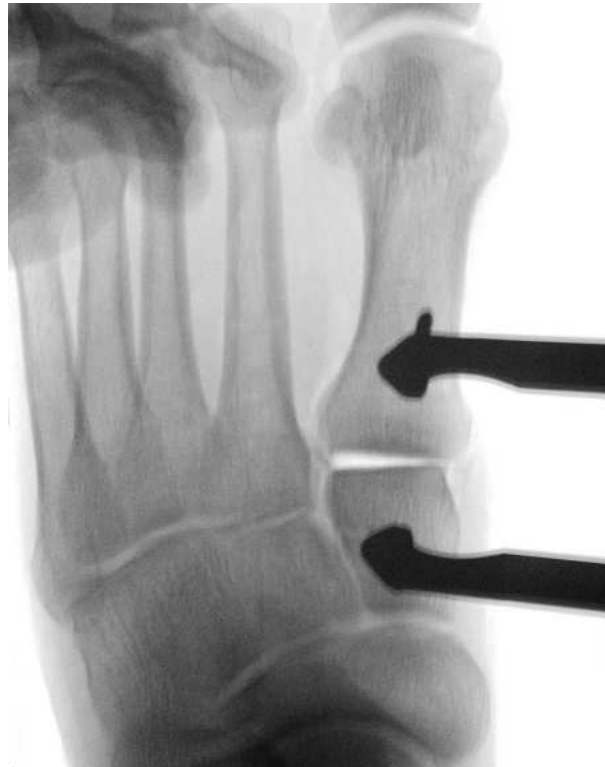---

The Compressor may be used for moderate distraction of the TMT joint if desired for visualization. Use a pituitary or a long, straight rongeur to remove the bone slices and/or any remaining plantar fragments of bone. Inspect the joint surfaces to confirm that all articular cartilage has been removed (particularly the medial aspect of the cuneiform), using a curette as necessary to remove residual cartilage.



Obtain a “down the joint” AP fluoro view to confirm that all remaining fragments of bone have been completely removed from the joint and that the cuts removed the full extent of the metatarsal and cuneiform articular surfaces.

**Note:** *If it is desired to irrigate the 1st TMT joint with saline, perform it prior to fenestration of the joint surfaces.*

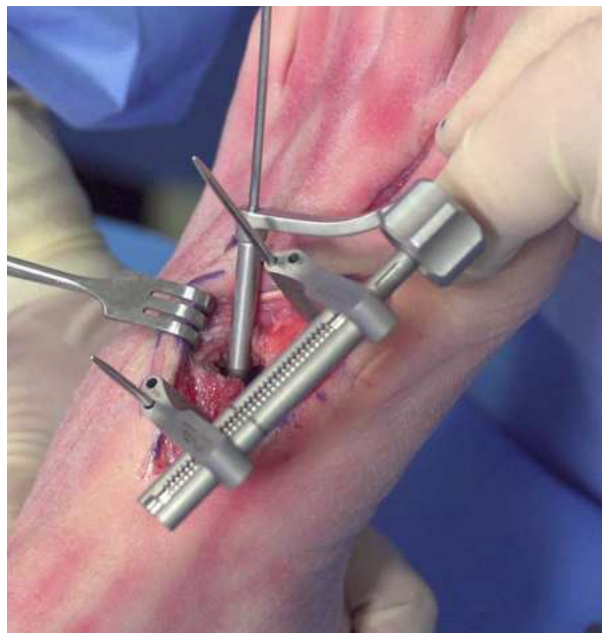



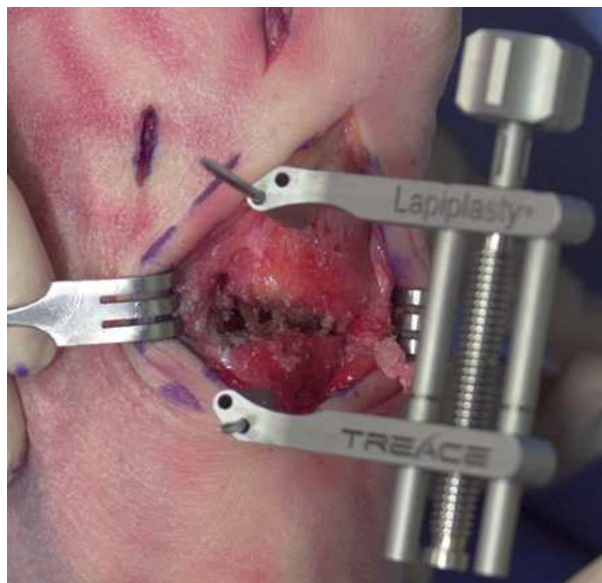
## Prepare the Joint Surfaces

---

With the 1st TMT joint distracted, use the 2mm straight fluted drill with optional drill sleeve to aggressively fenestrate the subchondral surfaces of the metatarsal and cuneiform. Make at least 10 holes per side to expose additional bleeding bone for bone healing.



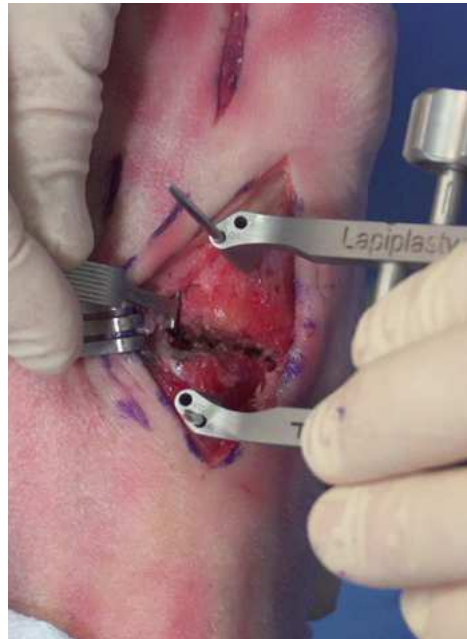Use a freer to push all the exposed, drilled bone into the TMT joint to serve as autogenous bone graft. Do not irrigate the joint after fenestration.



## Joint Apposition with the Compressor

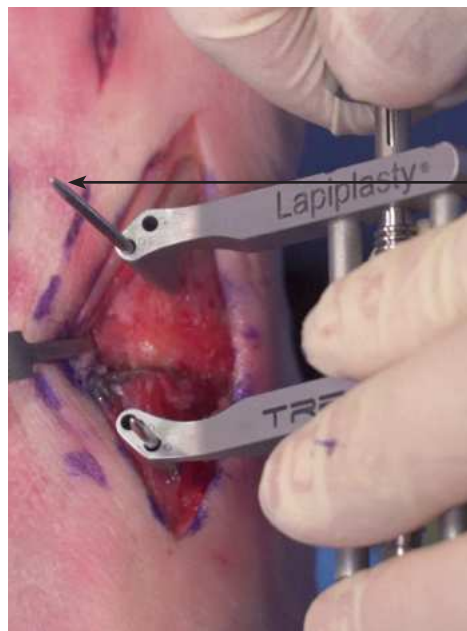
---

Begin tightening the **Compressor** until the joint surfaces start to touch, checking that the 1st metatarsal base is not translated dorsally or plantarly relative to the cuneiform. Insert the **Fulcrum** (1mm side is recommended) to act as a spacer between the 1st and 2nd metatarsal bases.



While holding the **Compressor** perpendicular to the AP axis of the foot (putting lateral pressure on the metatarsal pin), tighten the **Compressor** to compress the 1st TMT joint surfaces together utilizing “two-finger tightness”.

**Note:** Pay close attention to not overtighten the **Compressor**. If the 1st TMT surfaces are not fully compressing (particularly on the lateral and plantar aspects of the joint), back off the **Compressor** to check for residual bone fragments and/or soft-tissue impeding complete apposition.



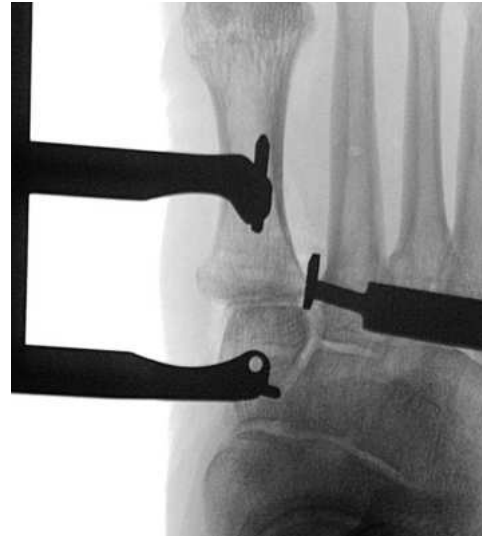Hold **Compressor** perpendicular to foot and apply lateral pressure to Metatarsal pin

## Confirm Joint Apposition

---

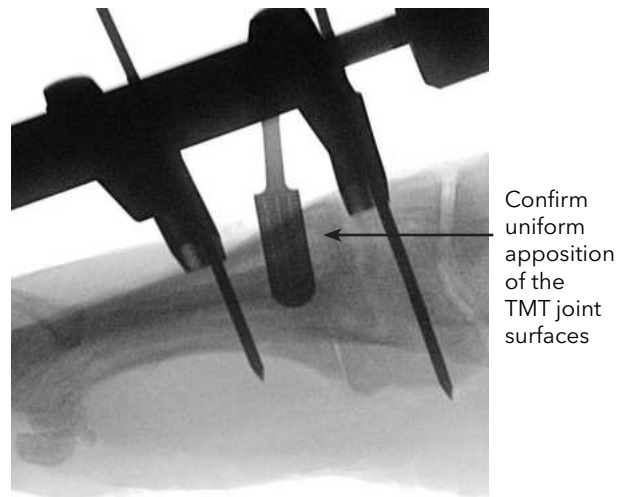
Obtain a “down the joint” AP fluoro image to confirm complete apposition of the 1st TMT joint surfaces (critically evaluating the lateral aspect of the joint) and maintenance of correction.

**Note:** *If there is a substantial lateral gap at the 1st TMT joint, consider reapplying the **Compressor** with the following suggestions: wedge the **Fulcrum** at the far proximal base of the 1st metatarsal, apply a lateral “twisting” force to the **Compressor** and/or metatarsal pin when compressing, and/or shave the lateral 1st metatarsal flare if it is impinging on the 2nd metatarsal.*



Obtain “down the joint” and standard Lateral fluoro-images to confirm complete apposition of the 1st TMT joint surfaces (critically evaluating the plantar aspect of the joint) and absence of 1st metatarsal dorsiflexion. If the pins are not bi-cortical, loosen the **Compressor** and insert them deeper into the respective bone.

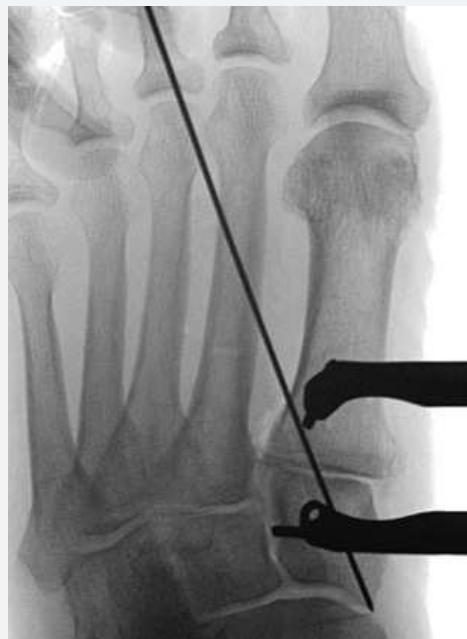**Note:** *A rigid, flat surface can be used to apply plantar pressure to the foot to simulate weight-bearing.*



## Insert Lateral Interfrag Screw [Alternative Option]

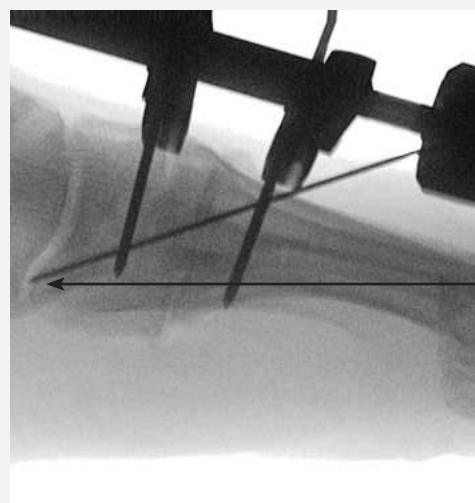
If an **Interfrag Screw** is desired, insert the 1.1mm K-wire from the lateral aspect of the 1st metatarsal (starting at the level of the **Compressor** pin) across the 1st TMT joint into the center of the cuneiform. Obtain an AP fluoro image to confirm the position of the K-wire, checking for interference with the Compressor pins and/or provisional fixation.

**Caution:** Care must be taken to ensure the k-wire is placed a sufficient distance from the TMT joint to avoid fracturing the bone.



Obtain a Lateral fluoro image to confirm the position of the K-wire, checking that it is in the plantar extent of the cuneiform to ensure plantar 1st TMT compression and to leave space for plate application.

**Note:** Reference the depth markings on the K-wire and cannulated drill to determine the appropriate length Interfrag Screw.



Place  
K-wire in  
plantar  
aspect of  
Cuneiform

## Insert Lateral Interfrag Screw [Alternative Option] (cont'd) \_\_\_\_\_

Select the appropriate **Interfrag Screw**, cannulated countersink, and corresponding cannulated drill. To ensure complete seating of the screw, the appropriate size countersink can be inserted over the K-wire, and advanced in a clockwise motion to penetrate the cortex. Advance the drill on power over the K-wire until the desired depth is achieved (noting the depth markings on the drill). Keep the drill spinning forward while removing the drill, taking care to not remove the K-wire as the drill comes out.

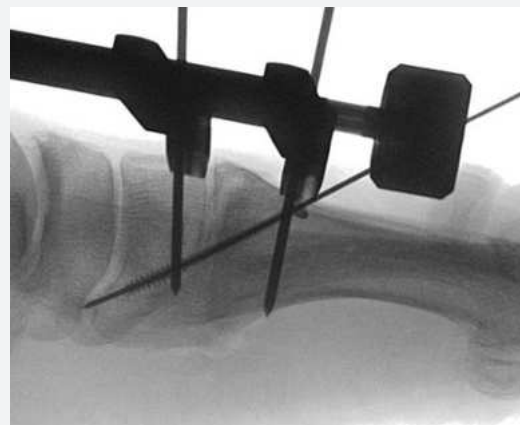
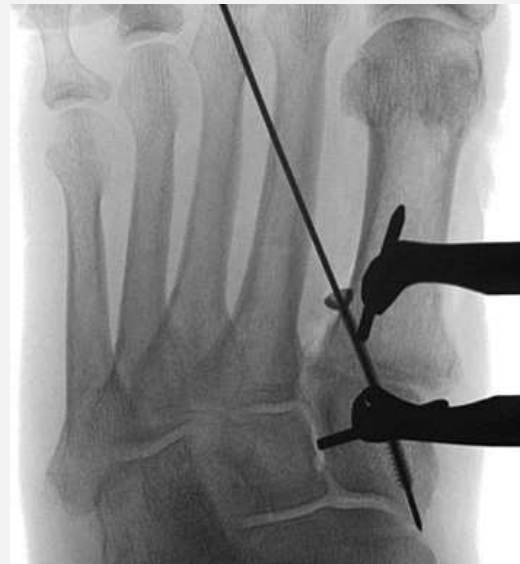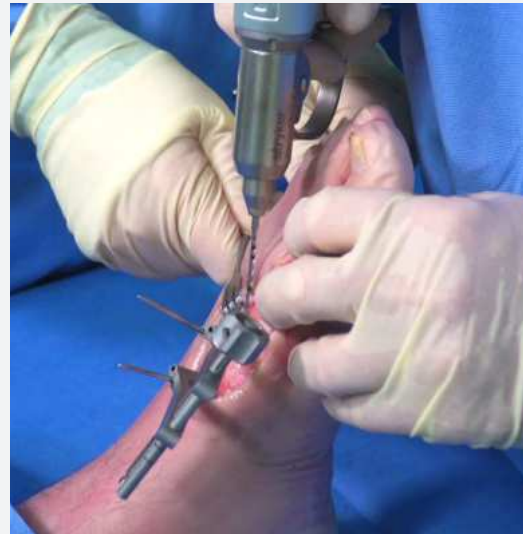**Note:** *Countersinking is an optional step and can be performed before or after drilling.*

**Caution:** *Removing too much bone with the countersink can cause loss of screw head purchase and diminish the compression effect of the screw.*

Advance the **Interfrag Screw** over the K-wire using the cannulated #15 AO screw driver tip on the ratcheting driver handle. Obtain AP and Lateral fluoro views for confirmation of the final position and length of the Interfrag Screw.

**Note:** *A second screw may be placed across the TMT joint as deemed necessary by the surgeon. It is recommended to place the screw from a proximal-dorsal to distal-plantar direction. Implant the second screw following same steps as described for the first screw.*

**Caution:** *Care must be taken to ensure the second screw is placed a sufficient distance from the first screw to avoid creating a stress riser.*



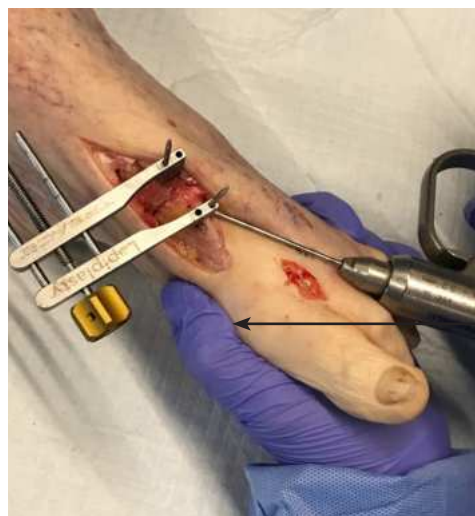

## Provisional Fixation with Threaded Olive Wire

---

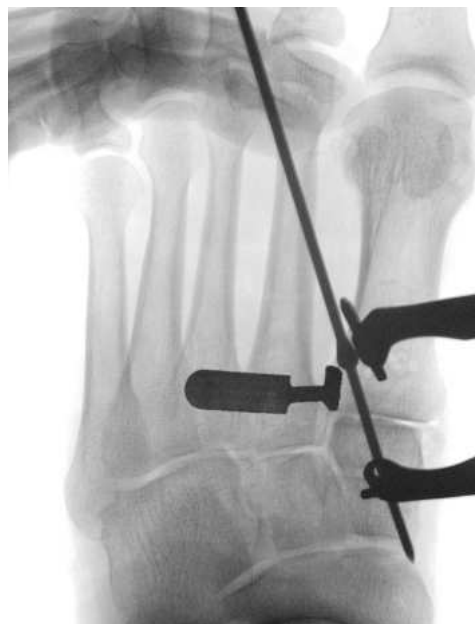While manually squeezing the foot (1st and 5th metatarsals) together with one hand, provisionally secure the 1st TMT joint with the 2mm threaded olive wire (40mm sub-olive length) from the lateral aspect of the 1st metatarsal across the 1st TMT joint into the center of the cuneiform. If resistance or contact with a pin/K-wire is encountered, reverse out the 2.0mm threaded olive wire and reinsert at a different trajectory.

**Note:** Start the 2.0mm threaded olive wire off the lateral aspect of the 1st metatarsal (starting at the level of the distal **Compressor** pin) to avoid interference with the dorsolateral **Biplanar™** Plate.

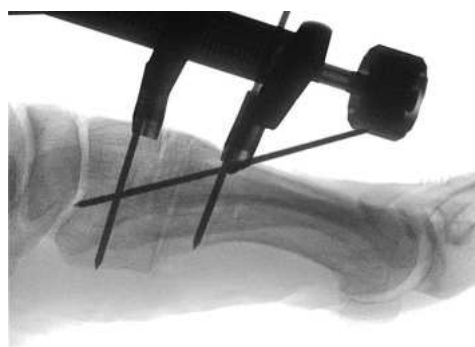


Manually squeeze the foot to close the IMA and reduce any small lateral TMT joint gap

Check a “down the joint” AP fluoro view to confirm the position of the 2.0mm lateral threaded olive wire, along with complete apposition of the 1st TMT joint and maintenance of the correction.

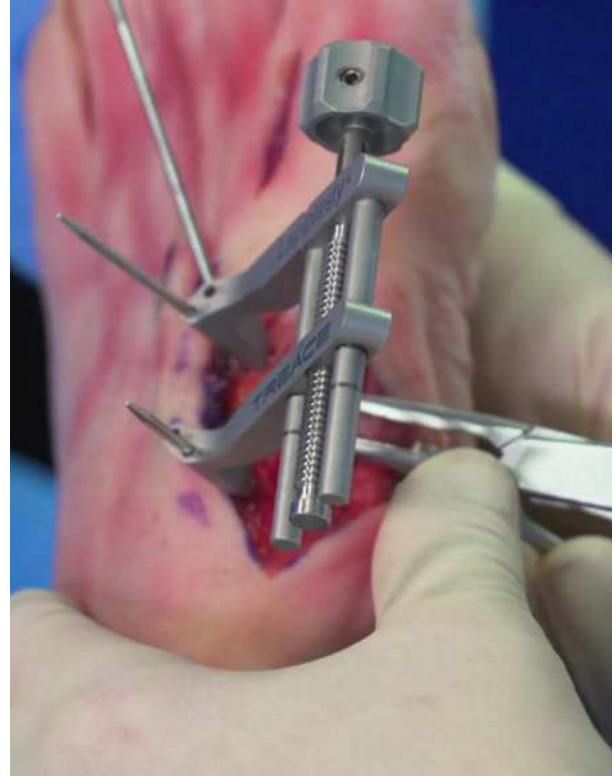


A Lateral fluoro can be checked to confirm position of the 2mm threaded olive wire, apposition of the 1st TMT joint, and sagittal alignment of the 1st metatarsal.



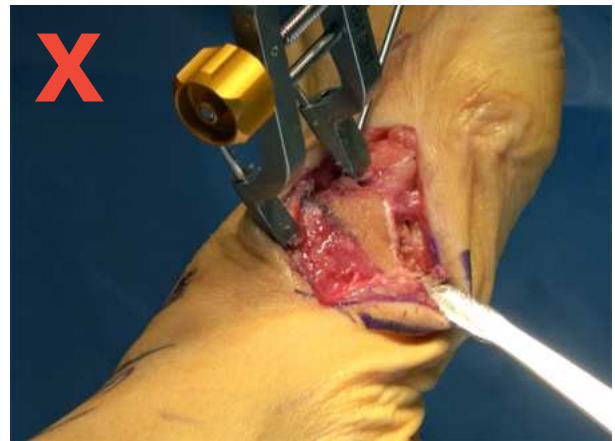## Provisional Fixation with Threaded Olive Wire (cont'd) \_\_\_\_\_

If there is a small medial step-off between the base of the 1st metatarsal and cuneiform, place a **Biplanar™ Plate** across it to assess the fit relative to the contour of the plate. If necessary, use a rongeur to conservatively contour this area (or shave it with the sagittal saw) to fit the natural curvature of the **Biplanar™ Plates**.



**Note:** Do not completely flatten the medial cortex as the **Biplanar™ Plates** have a natural curvature to fit the contour of the medial base of the 1st metatarsal.

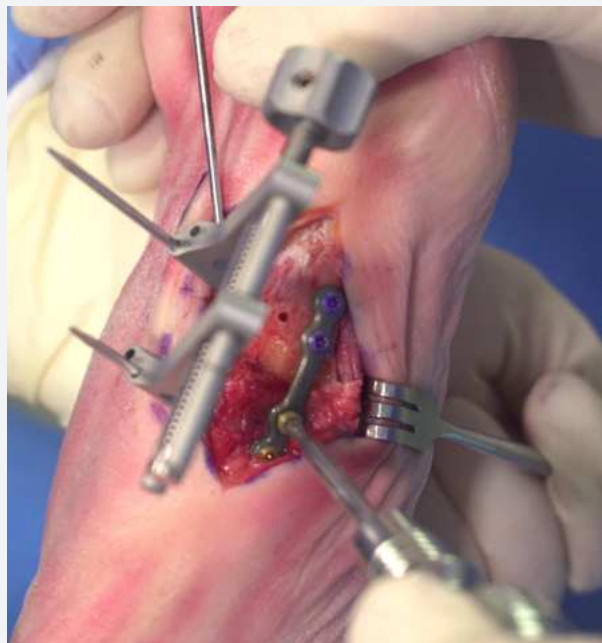Further, excessive bone resection may remove the cortex in the region where the uni-cortical locking screws will be inserted.



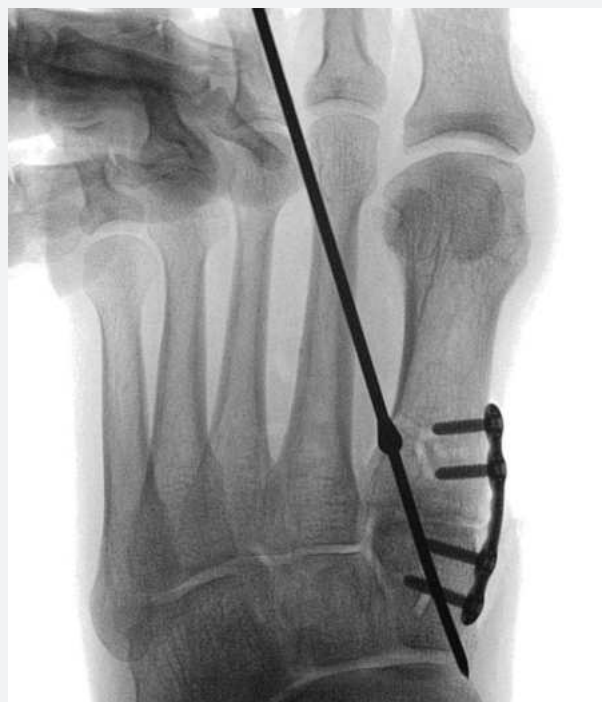## Apply Medial Biplanar™ Plate First [Alternative Option] \_\_\_\_\_

Optionally, the medial **Biplanar™ Plate** can be placed first (with the **Compressor** and 2.0mm threaded olive wire temporarily holding the 1st TMT joint). Select the appropriate **Biplanar™ Plate** and position it centered over the fusion site and direct medial (along the medial ridge of the 1st metatarsal), to ensure the screws will be oriented 90° to the dorsolateral **Biplanar™ Plate** screws. See pg. 41 for more detailed instructions on proper plate application.

**Note:** When placing the medial **Biplanar™ Plate**, it is recommended to leave the curvature in the plate (avoid excessively flattening it) such that the ends of the plate are contacting the bone and the plate contour reinforces the transverse-plane correction.



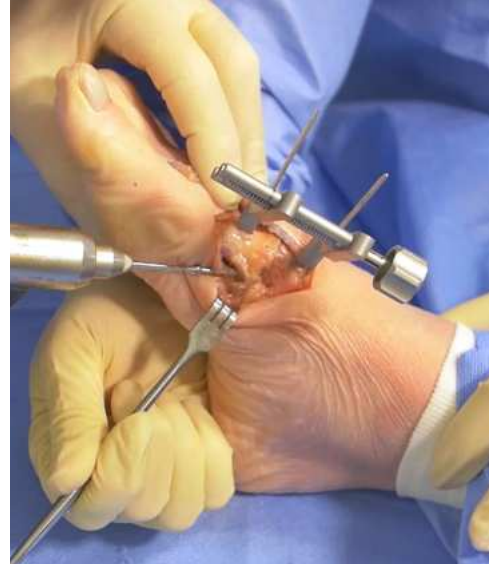To remove the **Compressor**, remove the 2.0mm half-pins from the **Compressor** (do not loosen the **Compressor** as it will distract the TMT joint). Confirm maintenance of correction on AP and Lateral fluoro views before proceeding to applying the dorsal-lateral **Biplanar™ Plate**. Always leave the 2.0mm threaded olive wire in place until both plates are applied.



## Apply 2nd Provisional Fixation Wire

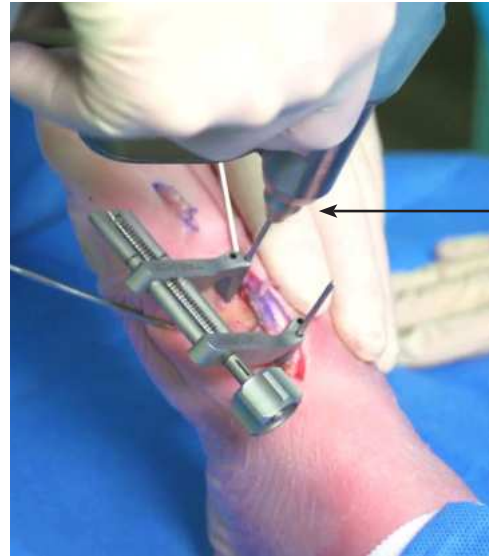
---

Utilize another 2.0mm threaded olive wire (or a 1.6mm K-wire) for a second point of temporary fixation. Position the olive wire from the plantar-medial aspect of the 1st metatarsal, crossing the plantar half of the 1st TMT joint into the cuneiform, to temporarily secure the plantar aspect of the 1st TMT joint. If resistance or contact with a pin/K-wire is encountered, reverse out the 2.0mm threaded olive wire and reinsert at a different trajectory.



With the position of the temporary fixation confirmed, remove the 2.0mm half-pins from the **Compressor** to remove the **Compressor** from the 1st TMT joint.

**Note:** Do not loosen the knob of the **Compressor** to remove it, as this will distract open the 1st TMT joint.

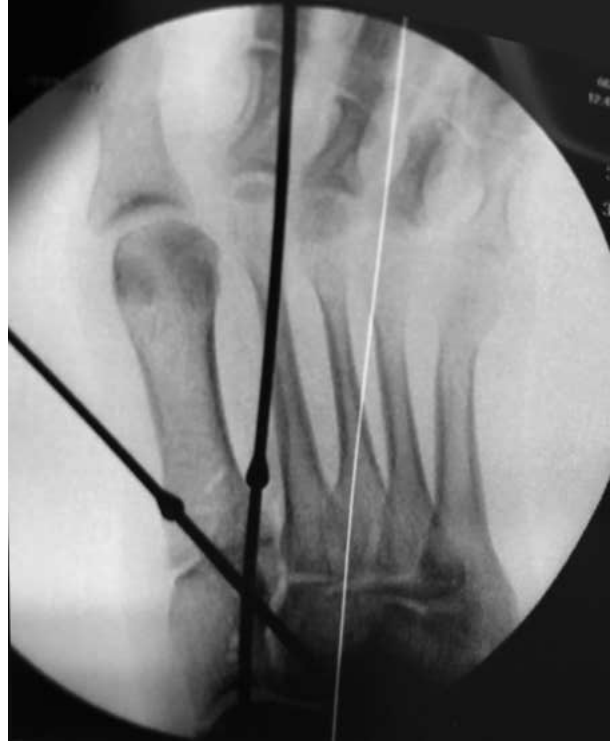

Remove pin to remove the **Compressor** without loosening it

## Confirm Provisional Fixation

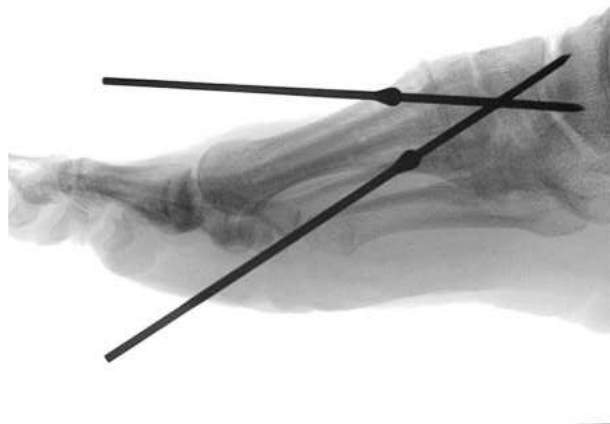
---

Before proceeding to plating, obtain an AP fluoro view to confirm complete apposition of the 1st TMT joint and maintenance of the correction.



A Lateral fluoro can be checked to confirm apposition of the 1st TMT joint and sagittal alignment of the 1st metatarsal.

**Note:** *If additional security of the 3-plane correction is desired, the **Positioner** and **Fulcrum** can be lightly reapplied at this step.*





# Apply Dorsolateral Biplanar Plate

---

Position the dorsolateral **Biplanar™ Plate** across the dorsolateral aspect of the 1st TMT joint, centered over the joint line. Check that both ends of the plate are contacting bone (rongeur the dorsal aspect of the 1st TMT joint as necessary) and the proximal screw holes are not in the intercuneiform joint.

**Note:** When placing the **Biplanar™ Plates**, it is recommended to leave the curvature in the plate (avoid excessively flattening it) such that the ends of the plate are contacting bone and the plate contours are reinforcing the sagittal and transverse-plane correction, respectively.

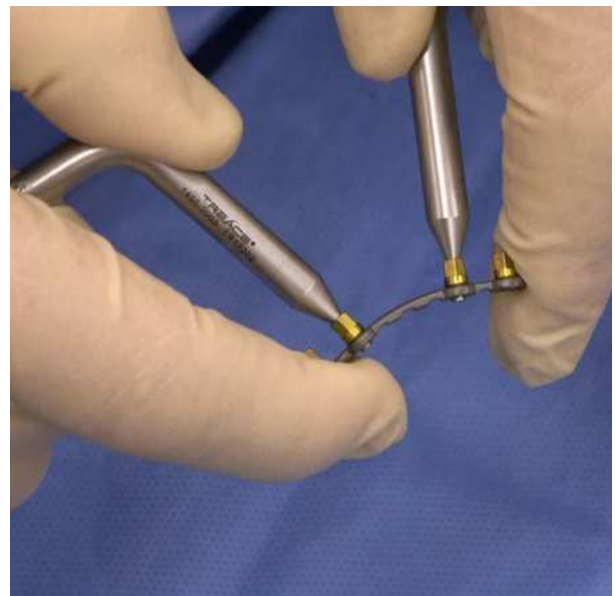
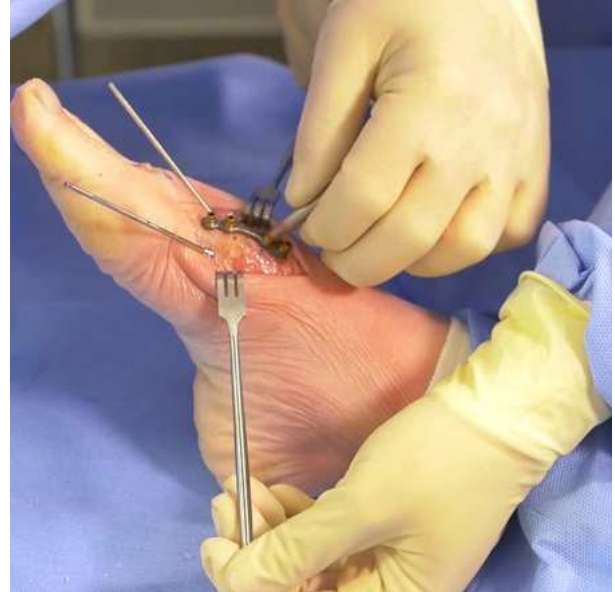If bending of the **Biplanar™ Plate** is required to match the bony anatomy, insert the plate benders into the pre-assembled drill guides on the plate and manually adjust the curvature prior to fixating to the bone.

**Note:** The plate benders are the only instrument that should interface with the plate/drill guides when bending the plate.

**Caution:** Bending should only be performed with the bending devices inserted into drill guides installed on the plate. Do not bend the plate without all the drill guides installed.

**Caution:** Each bend should be in one direction only; reverse or repeated bending may weaken or cause the plate to break.

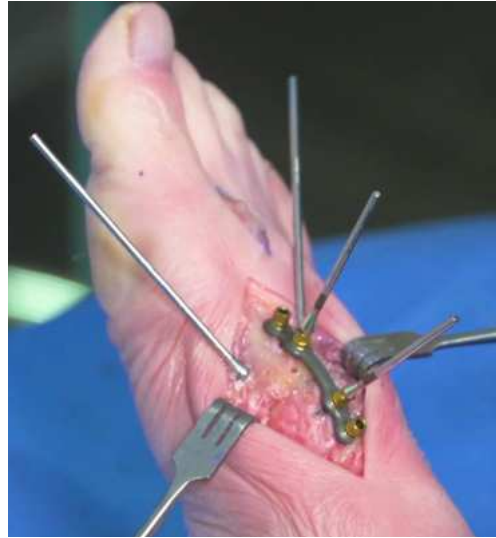**Caution:** TMC plates are not designed to be cut.



## Apply Dorsolateral Biplanar Plate (cont'd) \_\_\_\_\_

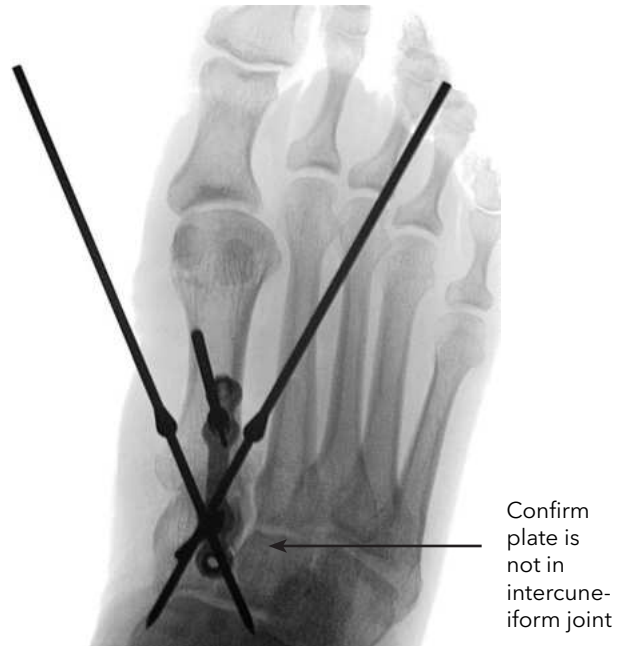Provisionally pin the inner holes of the dorsolateral **Biplanar™ Plate** in place with two 1mm plate tacks (marked with black bands just above the olive) to stabilize the plate on the bone and predict the locking screw trajectory.

**Note:** *It is recommended to utilize the 1mm plate tacks (versus the 2.2mm plate tacks) to avoid drilling multiple larger-diameter holes in the bone when positioning the plate.*



Confirm the position of the dorsolateral **Biplanar™ Plate** on an AP fluoro, checking that the plate is lateral to the midline and the screw trajectories are not in the intercuneiform joint.

**Note:** *A small, 15 gauge needle can be inserted in the intercuneiform joint as a reference when positioning the dorsolateral plate.*



## Apply Dorsolateral Biplanar Plate (cont'd)

Using the long olive wire with 2.2mm drill tip, drill through the two open drill guides. The long length of the olive drill shaft is designed to provide clearance when drilling next to the plate tacks.

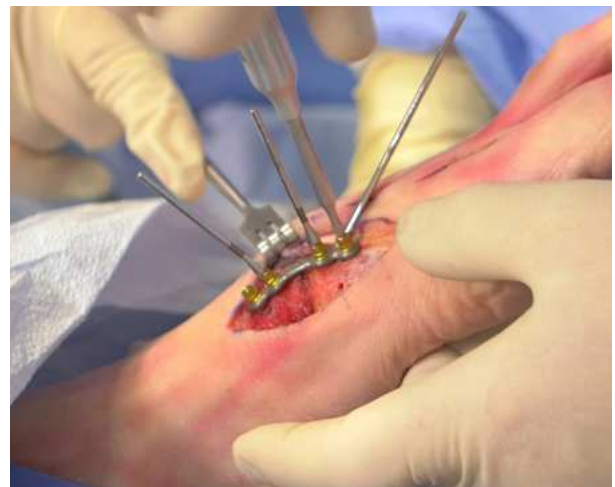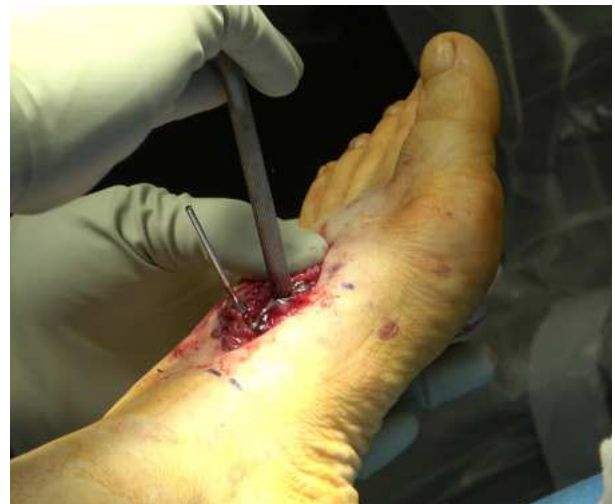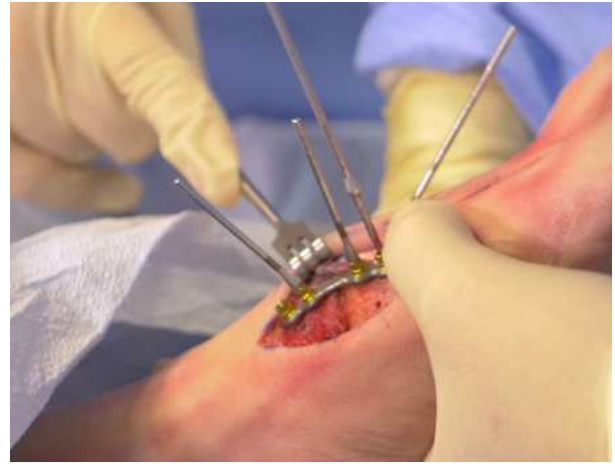
**Note:** *The Biplanar™ Plates utilize uni-cortical locking screws, so measurement of screw length is not required.*

**Note:** *If there is interference with the drill and the threaded olive wire(s), either adjust the plate position or come back to drill the hole after the threaded olive wire(s) have been removed following insertion of the remaining plate and screws.*

Remove the drill guide assembly from the plate by inserting the female hex wrench feature (on the back end of the plate bender handles) over the drill guide and turning counterclockwise. Remove the drill guides from the surgical site.

**Note:** *Alternatively, the drill guide assemblies can be removed by inserting the #8 star driver firmly into the drill guide.*

**Note:** *Do not discard the drill guide assemblies as they must be reapplied to the plates if redrilling of the screw holes is required.*

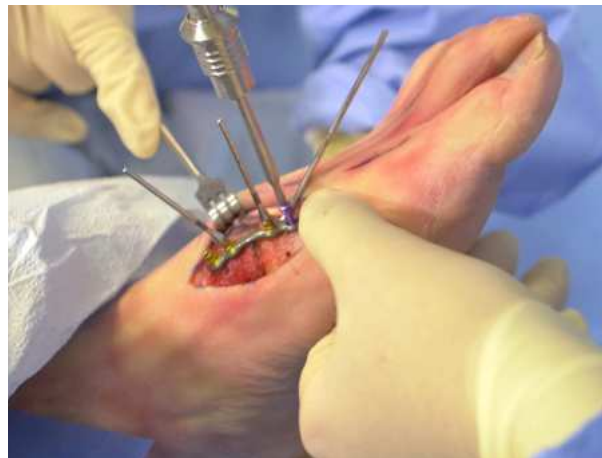

## Insert Locking Screws in Dorsolateral Plate

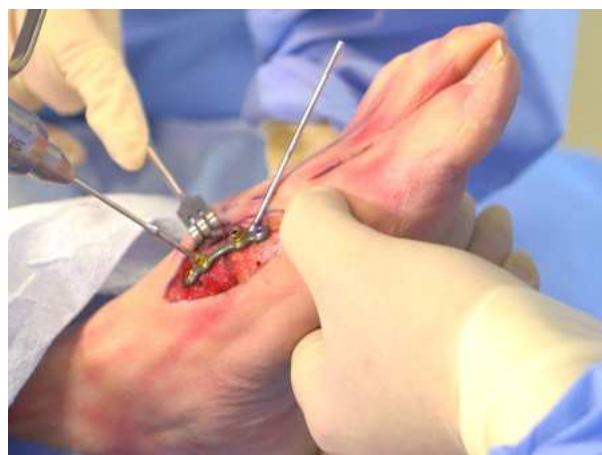---

Using hand pressure, insert a 12mm locking screw (magenta) onto the #8 star driver. Insert the screw centered and parallel with the pre-drilled distal plate hole until the head is completely flush with the plate and a firm stop is achieved. Insert a 14mm locking screw (gold) into the pre-drilled proximal hole.

**Note:** *The Lapiplasty® 2.7mm x 16mm and 18mm locking screws and 3.0mm x 18mm and 20mm locking screws can be used in place of the provided locking screws as deemed necessary by the surgeon.*



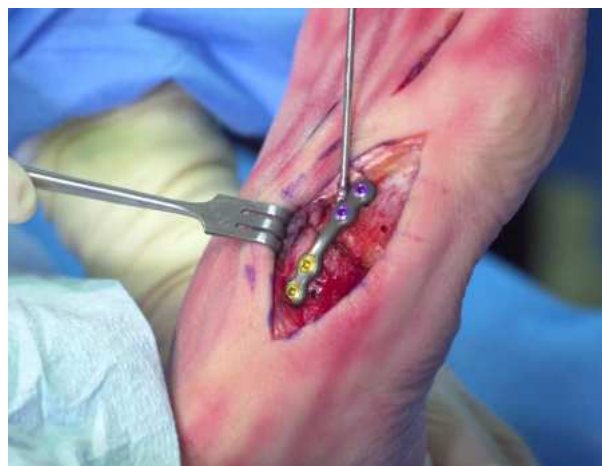Remove the 1.1mm plate tacks from the plate and drill the remaining holes using the olive wire with 2.2mm drill tip. Remove the respective drill guides after drilling.



Insert the two additional locking screws in the center holes, placing a 14mm locking screw (gold) in the proximal plate hole and a 12mm locking screw (magenta) in the distal plate hole.

**Caution:** *Use care to not cross threads while inserting the locking screws into the plates.*

**Caution:** *Use care to not over-tighten once the screw head locks into the plate, as this can result in stripping of the screw head and/or deforming the driver tip.*

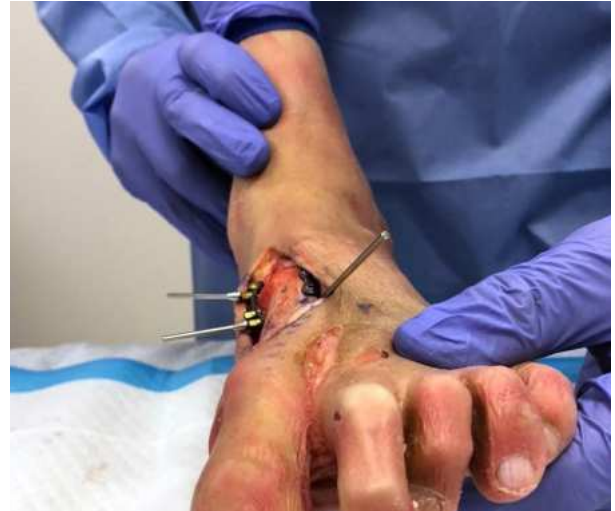



## Apply Medial Biplanar™ Plates

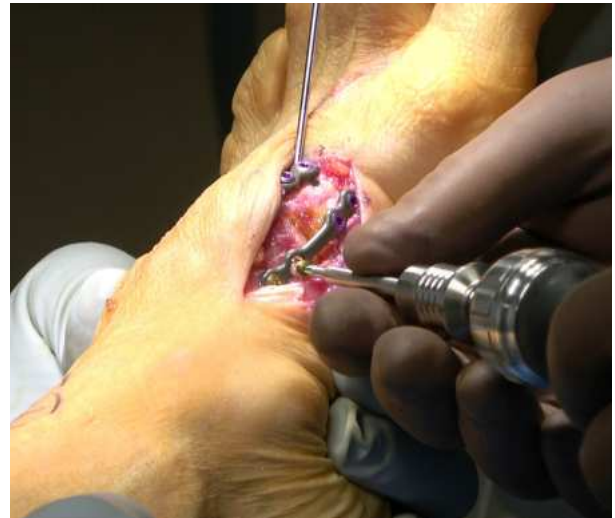---

Using the 1.1mm plate tacks or the 2.2mm short drill tacks, provisionally pin the second **Biplanar™ Plate** direct medial, along the medial ridge of the 1st metatarsal (ensure the screws will be oriented 90° to the screws in the dorsal-lateral plate). Install the second plate following the same steps as described for the first plate.



Insert two 12mm locking screws (magenta) into the distal end of the plate and 14mm locking screws (gold) into the proximal end of the plate.

**Note:** Care should be taken to avoid extensive dissection or periosteal stripping. Do not perform extensive undermining or dissection of the tibialis tendon insertion.



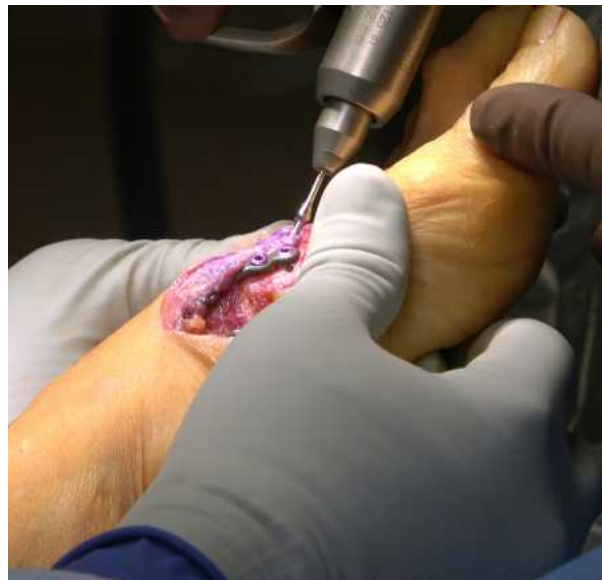

## Apply Biplanar™ Plates (cont'd)

---

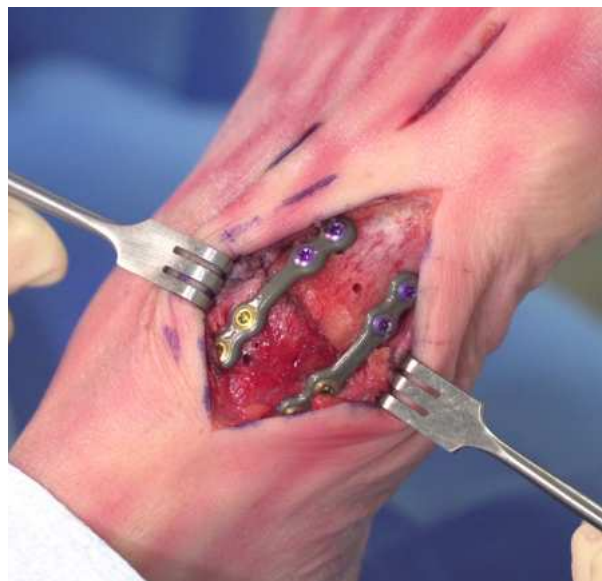Remove the 2.0mm threaded olive wire(s) or 1.6mm K-wire(s) used for provisional fixation, ensuring that the drill is on reverse when backing them out.

**Note:** *In order to maintain the correction while applying the **Biplanar™ Plates**, the lateral 2.0mm threaded olive wires should be left in place until plating is complete.*



Inspect the **Biplanar™ Plating** construct to ensure that all screws are fully locked flush with the plate surface, tightening all the screws before closing.

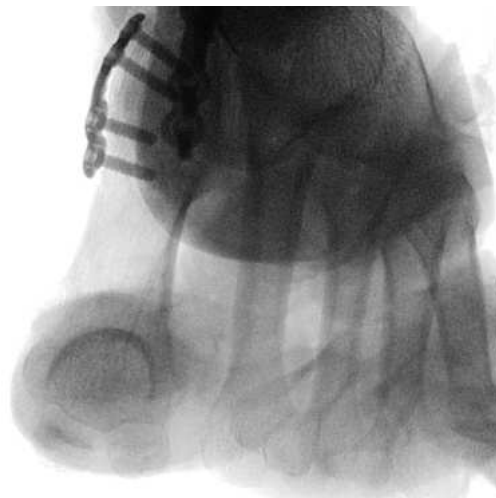
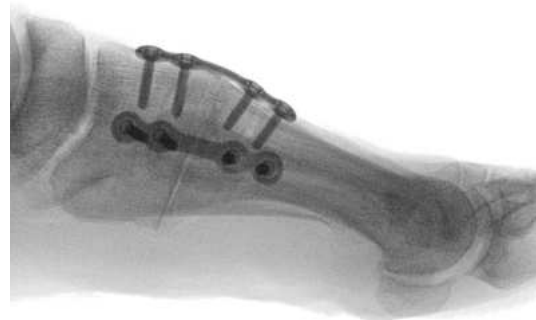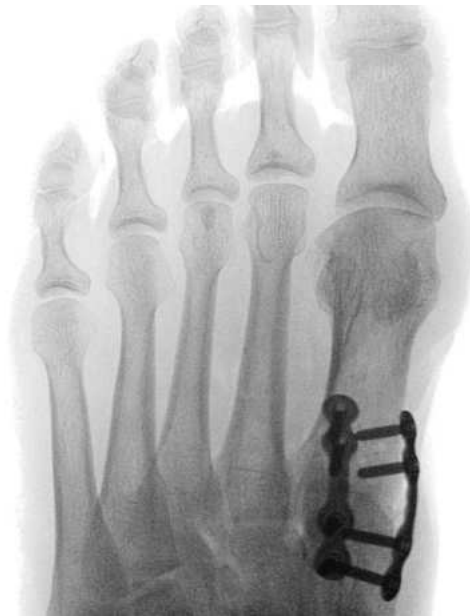**Caution:** *Be sure to remove all drill guides from the surgical site prior to closing.*



## Confirm Three-Plane Correction

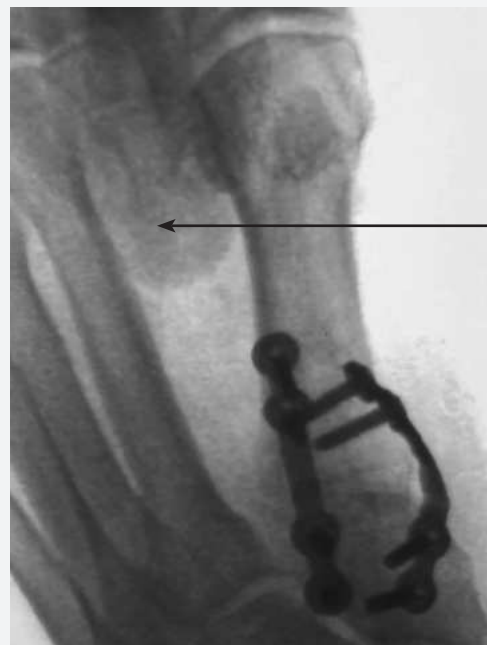---

Obtain AP, Lateral, and Axial Sesamoid fluoro views to confirm the final 3-plane correction and apposition of the 1st TMT joint surfaces.



## Insert Transverse Screw [Alternative Option]

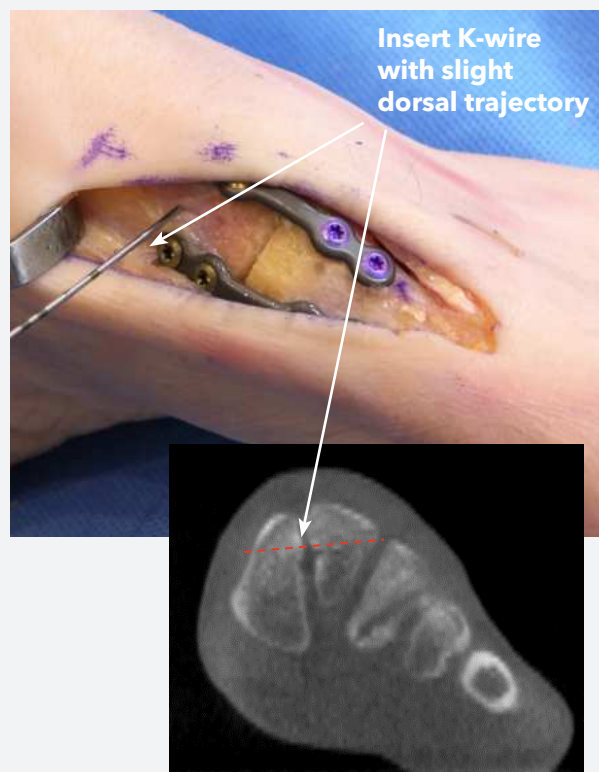
Under live fluoro, perform a “first ray splay test” to assess for excessive transverse-plane instability by manually applying pressure with your thumb and forefinger between the 1st and 2nd metatarsal heads.



Squeeze between 1st and 2nd Metatarsals for “splay test”

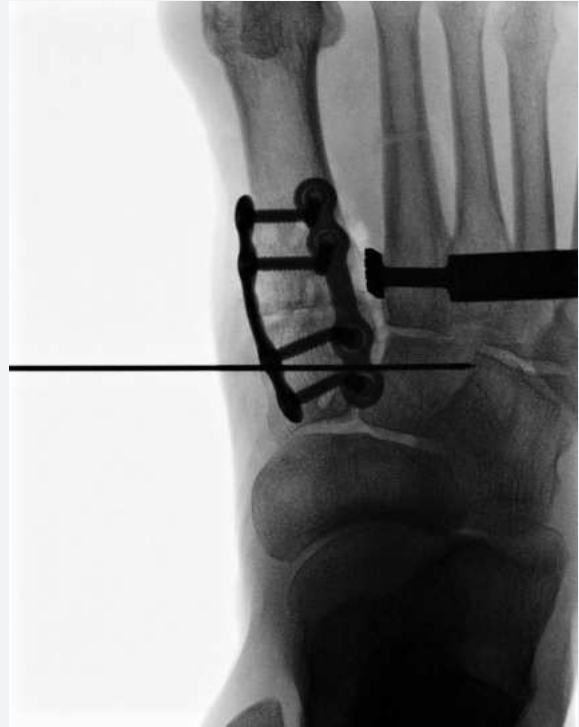If instability is detected, a **Transverse Screw** can be inserted for intercuneiform stabilization following the same steps described for the Interfrag Screw. Insert the 1.1mm K-wire between the **Biplanar™ Plates** and into the intermediate cuneiform, orienting with a slight dorsal trajectory due to the triangular cross-sectional shape of the intermediate cuneiform (noting the depth reference on the K-wire).

**Note:** The **Positioner** can be reapplied to compress the intercuneiform joint space while inserting the **Transverse Screw**.

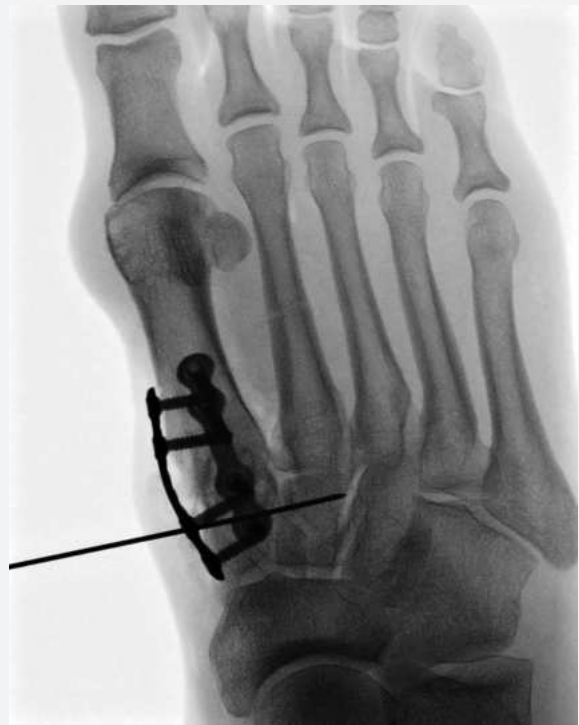

## Insert Transverse Screw [Alternative Option] (cont'd)

Obtain an AP fluoro to confirm that proper position of the K-wire, checking that is not positioned in the 2nd TMT joint.

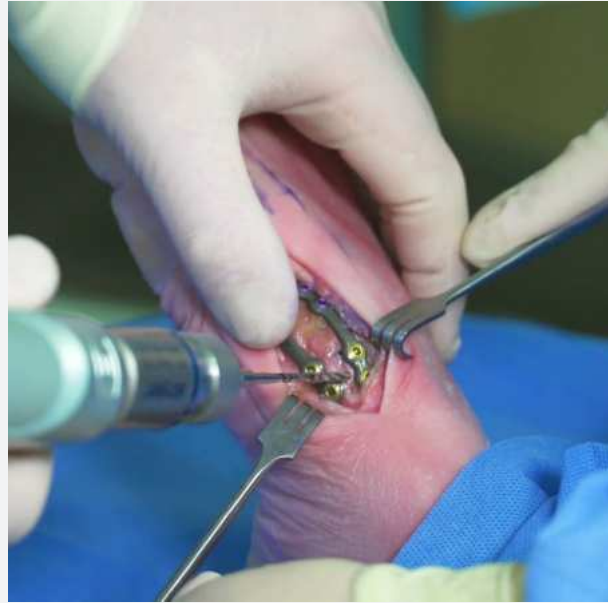

Pronate the foot under live fluoro to obtain a Lateral Oblique fluoro view looking between the 2nd and 3rd cuneiform joints to select the appropriate length of **Transverse Screw** (noting the depth markings on the K-wire).



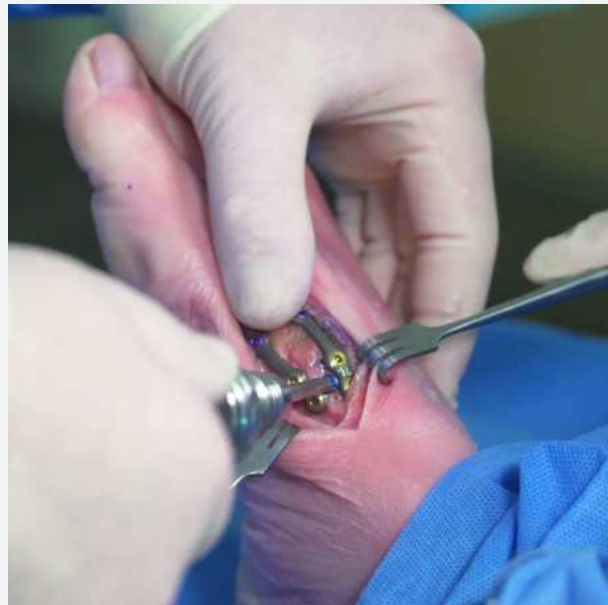## Insert Transverse Screw [Alternative Option] (cont'd) \_\_\_\_\_

Select the appropriate size cannulated drill and advance on power over the K-wire until the desired depth is achieved (noting the depth markings on the drill). Keep the drill spinning forward while removing the drill, taking care to not remove the K-wire as the drill comes out.



Advance the **Transverse Screw** over the K-wire using the cannulated #15 AO screw driver tip on the ratcheting driver handle.

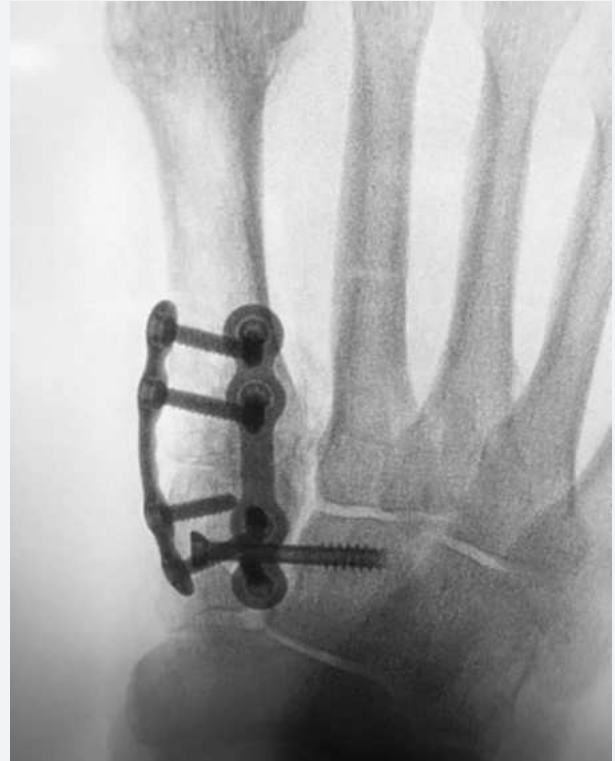**Note:** To ensure complete seating of the *Transverse Screw*, a cannulated countersink may be used.



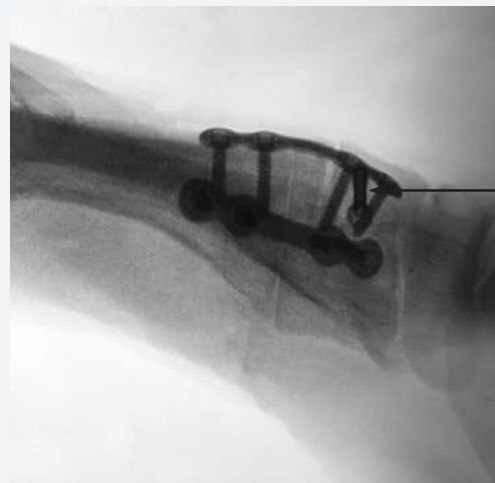

## Insert Transverse Screw [Alternative Option] (cont'd)\_\_\_\_\_

Obtain a AP fluoro view for confirmation of the final position and length of the **Transverse Screw**.



A Lateral fluoro view can also be obtained to confirm the final position of the **Transverse Screw** in the sagittal plane. Note the relative dorsal orientation of the **Transverse Screw** into the intermediate cuneiform.

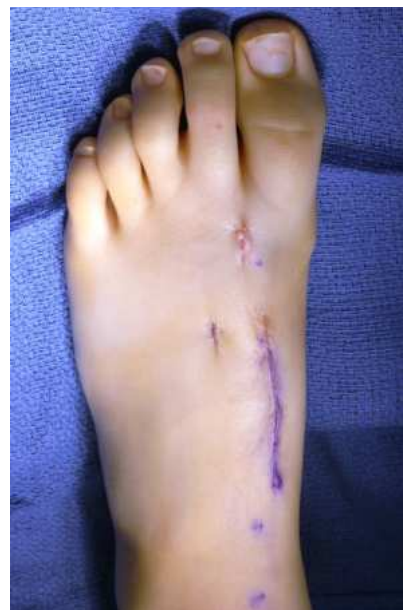
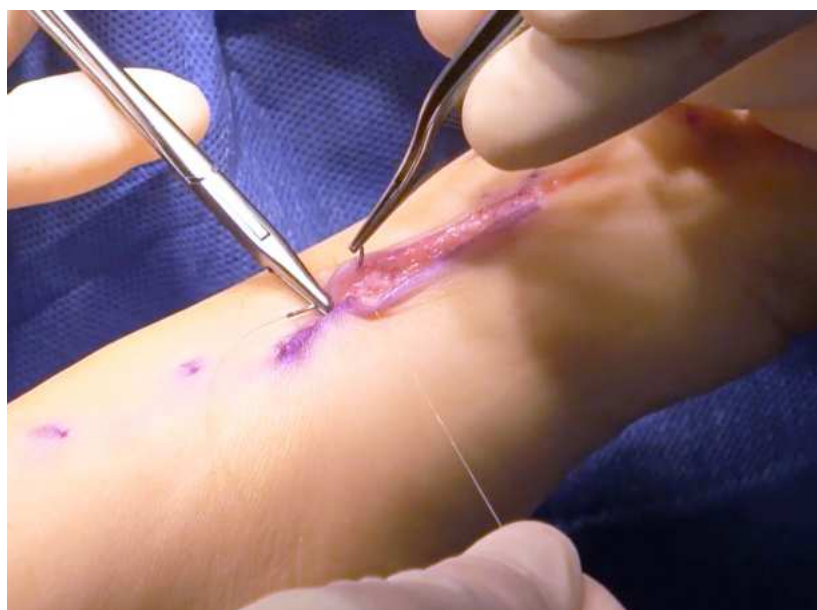
Slight dorsal orientation of Transverse Screw

## Final Incision Closure

---

Close the relevant tissue planes utilizing the preferred closure techniques. Note that a running stitch can be utilized for subcuticular closure in order to enhance the post-operative cosmesis.



This page left intentionally blank



203 Fort Wade Rd., Suite 150 Ponte Vedra, FL 32081 904.373.5940 [www.treace.com](http://www.treace.com)  
Pat. [treace.com/patents](http://treace.com/patents)  
LBL 1405-9149 Rev. A 07/20